# Die Hyperbare Sauerstofftherapie (HBO) im Therapiekonzept der

# Plastischen Chirurgie

## in den Druckkammerzentren des VDD e.V.

Verband Deutscher Druckkammerzentren

**Zusammenstellung von Informationen für Ärzte**

**Autor: Dr. med. Christian Heiden**
**Verband Deutscher Druckkammerzentren e.V. (VDD)**
**Cuno-Niggl-Str. 3, 83278 Traunstein**
**Tel. +49-861-12 589 Fax: +49-861-12 889**
**E-Mail: geschaeftsstelle@vdd-hbo.de**
www.vdd-hbo.de

**Stand: 130330**

# Inhaltsverzeichnis

# Einleitung

Die plastische und Wiederherstellungschirurgie steht oft vor der schwierigen Aufgabe trotz kompromittierter Spender- und Empfängerregionen für die Patienten zufriedenstellende Ergebnisse zu erreichen. Insbesondere in dieser Fachspezialität ist der Erfolgsdruck besonders intensiv.

Trotz bewährter Vorgehensweisen kann es teils zu vorhersehbaren teils zu überraschenden Problemen in der Heilung kommen.

Zu erwarten sind Probleme der Wundheilung oder der Einheilung von Lappen und Transplantaten in stark vernarbten oder gar bestrahlten Bereichen. Durch eine Rarefizierung der Kapillardichte in solchen Geweben sind diese hypozellulär, hypovaskulär und letztlich hypoxisch ( 3 H-Gewebe ). Nachdem Heilungsvorgänge von intakter Zellfunktion abhängen und der Zellstoffwechsel ausreichende Sauerstoffzufuhr verlangt, kommt es in hypoxischen Arealen regelmäßig zu Heilungsstörungen.

Die hyperbare Sauerstofftherapie (HBO) ist unter der Voraussetzung intakter großer Blutgefäße in der Lage Sauerstoffmangel auszugleichen. Die HBO wird seit den frühen 70er Jahren des letzten Jahrhunderts zur Besserung der Wundheilung und bei Verbrennungen erfolgreich eingesetzt und hat damit das Experimentalstadium lange verlassen. In vitro, in Tierversuchen und in hochrangigen klinischen Studien (bis Evidenzklasse 1a) ist dieser Effekt nachgewiesen. Der Oxygenierungseffekt ist transcutan und invasiv messbar. Voraussetzung für die Anwendung der HBO ist der Nachweis der Hypoxie und die Möglichkeit diese durch Sauerstoffatmung auszugleichen. Das wird schulmäßig weltweit vor Einleitung der HBO Behandlung bei Heilungsstörung in den Druckkammerzentren umgesetzt.

Der Einsatz der HBO hat folgende physiologische Effekte, die auch in der plastischen und Wiederherstellungschirurgie genutzt werden können:

1. **Aktivierung aller an Heilungsvorgängen beteiligter Zellsysteme**
2. **Neubildung von Kapillaren in hypovaskulären Regionen und in chronischen Wunden**
3. **Infektionsbekämpfung durch Aktivierung der zellulären Infektabwehr und durch Wirkungssteigerung etlicher Antibiotika**
4. **Ödemreduktion mit resultierender Schmerzlinderung und Durchblutungsverbesserung**
5. **Minderung von Reperfusionsschäden bei frühzeitigem Einsatz**

**Zu 1. Wirkung der HBO auf Wundheilung:**

- 2,0 bis 2,5 bar erhöhen pO2 auf > 1500 mmHg arteriell
- Hypoxiebeseitigung entsprechend dem gesteigerten Diffusionsgefälle ins hypoxische Areal
- multifunktioneller Signalstoff (Zytokin) TNF-α gesteigert
- Makrophagen - VEGF gesteigert
- wachstumsfaktor-spezifische Rezeptoren an Fibroblasten vermehrt
- Fibroblasten - Proliferation
- Gesteigerte Syntheseleistung für extrazelluläre Matrix, Hyaluronsäure und Proteoglykane
- Induktion von PDGF Rezeptoren
- Verringerung systemischer Entzündung
- Minderung der Toxinsynthese bei Anaerobiern

**Zu 2. Neovaskularisierung:**

Die HBO führt zu einer Neubildung von Kapillaren, die z.B. im bestrahlten Gebiet nach einer Kapillarenrarefizierung auf 20% des Normalen stabile Langzeitergebnisse mit Neubildung auf 80% zeitigt. Unter HBO gesteigerte angiogene Polypeptide zusammen mit FGF, PDGF, VEGF fördern das Aussprossen entlang der Laktatgradient und dem $O^2$ Gradienten. Ein hoher pO2 in Venolen am Wundrand fördert dises Kapillarenwachstum. (Ketchum et al. 1969; Gibson 1997; Bajrovic 1998; Sheikh et al. 00)

**Zu 3. Infektionsbekämpfung:**

Durch seine direkte Wirkung auf Bakterien, Verbesserung der zellulären Abwehrmechanismen des Körpers und synergistische Effekte auf die Wirkung von Antibiotika ist die HBO in Kombination mit Chirurgie und Antibiotika als adjuvante Therapie extrem nützlich bei der Behandlung von Gewebsinfektionen sowohl mit anaeroben als auch aeroben Bakterien in hypoxischen Wunden und Geweben. Ihre Nützlichkeit wurde klar belegt mit einer großen Zahl von in vitro und in vivo experimenteller Forschung und im Weiteren bestätigt durch extensive klinische Serien. Der Vorteil, den die HBO im Breich infektiöser Erkrankungen bewirkt ist vor allem auf die adaequate Wiederherstellung normaler oder übernormaler Sauerstoffpartialdrücke in hypoxischen infizierten Geweben zurückzuführen. (Mathieu et. al. 2006)

**Zu 4. Ödemreduktion**

Die HBO hat eine hohe Potenz zur Reduktion von Ödemen. So kann z.B. beim beginnenden Kompartmentsyndrom nach HBO in vielen Fällen auf die Faszienspaltung verzichtet werden (Evidenzklasse 1b). Die resultierende vasokonstriktion der Arteriolen mindert den hydrostatischen Druck in der Endstrombahn. Die Reabsorption von Ödem aus dem Interstitium wird dadurch unterstützt und ebenso die kapilläre Transsudation (capillary leak reduction). Der Circulus Vitiosus: Ödem-Hypoxie-Vasodilatation wird unterbrochen. Das „venöse Pooling“ nimmt ab. (Nylander et al.1985, Skyhar et al.1986, Strauss et al.1983 + 87, Wells et al. 1977)

**Zu 5. Reperfusionsschäden:**
Nach Durchblutungsminderung entstehen im noch nicht abgestorbenen Gewebe im Verlauf der Reperfusion zunehmende Schädigungen mit weiterem Gewebsuntergang. Unter HBO werden folgende Effekte zur Minderung der Reperfusionsschäden beobachtet:

- axiale Hautlappen überleben nach 8 Std. Ischämie signifikant häufiger
- Durchblutung von axialen Hautlappen ist nach 8 Std. Ischämie signifikant stärker
- mikroanastomisierte freie Lappen überleben nach Ischämie von bis zu 24 Std. signifikant besser
- verbessertes outcome durch Reduktion von Ödem und Nekrosen im Muskel bei Kompartmentsyndrom (Strauss 83)
- verbesserte Muskelfunktion 5 Wo nach Ischämie und HBO (Replantationschirurgie)
- Während und bis zu 4 Std. nach Ischämie – signifikante Minderung der Neutrophilenadhäsion an Venolen
- Beta-2-Integrin (CD18 Kette) des Leukozytenfunktionsantigen (LFA-1) an seiner Membranoberfläche wird geblockt, ohne Störung der sonstigen Leukozytenfunktionen
- Reduziert den Abfall von ATP und Phosphocreatin und den Anstieg von Laktat (Zellatmung) (Nylander 87;Sirsjö 90; Stewart 89)
- Phosphorylase wird reduziert (Marker für Muskelzellschaden) (Nylander 87)

(Zamboni 1989, 92, 93, 94, 96; Thom 90, 91, 93; Kolski 94; Matteson 93; Kaelin 90)

Aufgrund der vorliegenden zahlreichen Veröffentlichungen wurde die HBO-Therapie bei der Gefahr von Transplantatverlust von Medicare als evidenzbasiert eingestuft.
Damit ist in den USA – der Heimat der evidenzbasierten Medizin – die HBO unter weiteren anderen Indikationen zur Kostenübernahme durch das dortige allgemeine, soziale Krankenversicherungssystem akzeptiert und in das Behandlungskonzept solcher Erkrankungen auch integriert.

In der Anlage finden Sie eine Auswahl an Literatur die die hier aufgeführten Effekte belegen und damit die Behandlungsrationale für Problemfälle in der plastischen und Wiederherstellungschirurgie aufzeigen.

# Hyperbaric Oxygen Therapy in Plastic Surgery

**Harvey N. Himel, M.D., M.P.H.**
Director, DeCamp Burn and Wound Healing Center, University of Virginia Health Sciences Center

**Dick Clarke, C.H.T.**
Administrative and Clinical Director, Hyperbaric Medicine Program, Richland

Advances in Plastic und reconstructive surgery', vol. 13 1997, Mosby-Year Book, Inc.

Memorial Hospital, Columbia, South Carolina

Hyperbaric oxygen therapy (HBOT) is a systemic treatment defined as the inhalation of 100% oxygen delivered at an elevated ambient pressure, generally being two to three times that of atmospheric pressure. This combination of elevated pressure and increased concentration of oxygen establishes a gradient such that large amounts of oxygen dissolve into the arterial plasma. When the pressure is three times that of the atmosphere at sea level, or 3 atmospheres absolute (3 ATA), and is delivered into the plasma, it increases the oxygen carrying capacity of the blood. This is done by dissolving a large amount of oxygen into the plasma such that there is adequate oxygen delivery to maintain cell function in the absence of hemoglobin. This delivery of hyperoxygenated blood to the tissues results in a number of physiologic changes that produce the various benefits of hyperbaric oxygen.

## HISTORICAL PERSPECTIVE

Treating patients in a high pressure environment was described as early as 1664 by Henshaw (1) who worked with a crude pressurizing pump to deliver room air at various pressures both below and above that of atom-spheric to treat various illnesses. Two hundred years later, hyperbaric chambers were constructed and used empirically to treat a number of dis-orders, and were even used to combat aging in otherwise healthy indi viduals.2 Unfortunately, there was no scientific basis to support the vari-ous treatments and no rigorous data were collected to confirm claims of efficacy. In contrast, when Fontaine' began performing surgery in a large hyperbaric operating room in 1879, he noted decreased anesthetic-associated morbidity among a series of patients.

With the advent of commercially available oxygen, Cunningham built a hospital in Cleveland that was devoted to hyperbaric oxygen treatment. His rationale' was basecl on an unsubstantiated theory that anaerobic bacteria were the cause of cancer, diabetes, anemia, and other heretofore unexplained illnesses. His use of oxygen for treating patients with anaerobic infection was well founded, especially prior to the advent of penicillin, however, his hyperbaric hospital was otherwise widely criticized by the medical establishment5 for its empiric application to so many disorders with no biological basis. His hospital ultimately was dismantled in 1935.

The use of hyperbaric oxygen therapy for **decompression sickness** was the first widely accepted application for this modality. Decompression sickness can occur when a person returns to sea level atmospheric pres-sure too rapidly after spending a prolonged period of time breathing un-derground or underwater at elevated ambient pressure. The first clinical observation of decompression illness' occurred in the early 1800s when it was observed among construction workers who were using the Caisson to dig below river beds and construct tunnels and bridges. During the construction of the Brooklyn bridge, there was a very high mortality from decompression sickness, which was known at the time as "Caisson's disease." This illness is also known as the "bends" because the discomfort would cause patients to walk in a contorted manner. It was not until 1854 that insight was gained into the treatment, when coal miners, who developed the illness on rapid ascent, would return to the pressurized mine and

find their symptoms to be ameliorated.7 The use of hyperbaric oxygen (HBO) for the treatment of decompression sickness rests on a firm foundation of physical science and, along with arterial gas embolism, is one of two absolute indications for HBO.

Many of the current principles of undersea and hyperbaric medicine are based on research done by the military and commercial diving Industries. Observations on the effects of prolonged, deep dives and rapid decompression have led to the promulgation by the U.S. Navy of decompression tables," which remain the standard of reference among divers and compressed air workers for prevention of decompression sickness. These tables specify the amount of time needed for decompression maneuvers based on the amount of time spent at various pressures. The tables are used by HBO personnel, who must accompany their patients into air-filled multiplace and duoplace chambers (Fig 1) during treatment. Particularly, they must remain at elevated, ambient pressure for extended periods of time, breathing air containing nitrogen.

Early scientific study into the physiology of HBOT was carried out bv Boerema in the Netherlands. **He published a seminal work called "Life Without Blood,"9 which described the ability of his research team to keep experimental animals alive for an extended period of time with HBO, even after complete exsanguination and replacement of** their blood with hemoglobin-free substrate. Subsequently Brummelkampl reported the value of HBOT in treating **anaerobic infection**, confirming Cunningham's claim that HBO would help fight against anaerobic infection, but only in the specific case in which these organisms clearly were pathogens. An-other early use of HBOT, which remains in favor today, is as an adjunct in the treatment of **osteomyelitis**, first reported by Slack.11 Taking a lead from Boerema's laboratory studv, Attarl demonstrated the benefit of HBOT in treating **hemorrhagic shock**.

Churchill-Davidsonn explored the application of **HBO in radiation therapy**. He was searching for a method of enhancing cell kill by delivering more oxygen during irradiation of the lesion. Because all HBO cham-bers were constructed thus far from steel, the design had to be altered. An acrylic plastic chamber was used to allow radiation therapy to pro-ceed during HBO treatments, thus potentiating the radiation beam. As a result of the necessary design modification, the tost of construction feil, and hyperbaric oxygen chambers became more widely available. In the United States, the number of facilities has increased from 37 in 1977 to well more than 200 in 1995. Interestingly, radiation during HBO treat-ment has subsequently been studied by several radiation therapists, but remains under evaluation.'

Among the more intriguing HBO reports is the serendipitous observation by Weda' of a benefit in treating **thermal injury**. He treated a number of patients from a coal mine explosion, some of whom were given HBO for **carbon monoxide (CO) poisoning**, which they sustained in association with their thermal injury. Those who received HBO for the CO poisoning appeared to heal their cutaneous wounds faster and were discharged sooner than those with similar burns, but no CO poisoning and no HBO treatment. This observation was supported by laboratory studies reporting **improved vascularity in burn wounds** among animals receiving HBO as part of their treatment.16 Further interest in HBO as an adjunctive wound healing treatment came with Perrins' clinical report of improved survival for split-thickness skin grafts in patients. The patients were randomly assigned to HBO at 2 ATA for seven treatments beginning the evening after surgery and continuing twice a day thereafter.17

Concurrent with the interest in this treatment for soft tissue trauma and infection, it was noted that there were still manv indications being proffered that were not firmly grounded in scientific principles. As a re-sult, in 1977, the Undersea and Hvperbaric Medical Society (UHMS) formed an advisory committee that reviewed HBOT in all reported cat-egories of treatment. They produced a summary clocument based an a rig-orous review of all previous reports. The document culminated in a list of conditions in which HBOT would be considered the treatment of choice and conditions in which it would only be considered a valuable adjunctive treatment. This list was most recently updated in 1992 (Table 1). Despite this ongoing effort to seif-regulate the application of HBOT, reports of various, widely exaggerated benefits with no confirmed data continue to crop up from time to time. Interest in HBO and its accep-tance by the mainstream medical establishment continues to fluctuate,18 although supporting evidence continues to mount both in clinical research as well as in laboratory investigation.

**TABLE 1.**

Indications for Hyperbaric Oxygen 1997

1. Air or gas embolism
2. Carbon monoxide poisoning, acute smoke inhalation, assumed carbon monoxide/cyanide poisoning
3. Gas gangrene (clostridial)
4. Crush injury, compartment syndrome, and other acute traumatic ischemias
5. Decompression sickness
6. Enhancement of wound healing in selected patients
   a. Diabetic ulcers
   b. Venous stasis ulcers
   c. Arterial insufficiency ulcers
7. Exceptional blood loss (anemia)
8. Necrotizing soft tissue infections (subcutaneous tissue, muscle, and fascia)
   a. Crepitant anaerobic cellulitis
   b. Progressive bacterial gangrene
   c. Necrotizing fasciitis
   d. Nonclostridial myonecrosis
   e. Fournier's disease
   f. Miscellaneous necrotizing infections in the compromised host
9. Osteomyelitis, refractory
10. Radiation tissue damage: osteoradionecrosis or soft-tissue radiation necrosis, caries in radiated bones
11. Skin grafts or flaps (compromised)
12. Thermal burns

(Courtesy of Undersea and Hyperbaric Medical Society, *Hyperbaric Oxygen Therapy: A Committee Report,* 1992.)

## PHYSICS OF HYPERBARIC OXYGEN

At sea level, atmospheric pressure measures approximately 14.7 pounds per square inch (psi), or 760 millimeters mercury (mm Hg). When one dives into the ocean, pressure increases as one dives deeper, and the weight of the water exerts increasing pressure. At a depth of 33 feet below sea level, the pressure doubles to 1,520 mm Hg, and if one proceed down to 66 feet below sea level, the pressure becomes 3 times that mea-sured at sea level, or 2,280 mm Hg.

Pressure measurements during hyperbaric treatment are reported in two ways (Table 2). One can use the absolute pressure scale, whereby the ambient pressure is compared to the reference point of zero pressure found in a total vacuum. Gauge pressure is an alternative method, which uses the ambient pressure at sea level as an arbitrary reference point with a value of zero. Thus, atmospheric pressure, such as that reported by the weather service, is an absolute scale, whereas gauge pressure is a relative scale with the baseline of zero gauge at sea level pressure.

Inspection of the pressure conversion table shows how patients begin treatment at 0 atm gauge pressure, or 1 ATA, and patients who are treated at 2 atm of gauge pressure are treated in a pressurized environment corresponding to diving down to 66 feet of sea water (fsw) and 2,280 mm Hg of pressure. The pressure gauge an the chamber will read 1 ATA or 0 fsw at the start of pressurization, and will read 3 ATA or 66 fsw during treatment.

Atmospheric air is made up of a mixture of gases, primarily nitrogen, comprising approximately 78%, and oxygen, comprising approximately 21%. The remaining 1% of the air is composed of a number of rare gases including argon, carbon dioxide, neon, helium, krypton, xenon, hydrogen, methane, nitric oxide, and ozone in decreasing concentrations. Each of these gases contributes to atmospheric pressure according to Dalton's law of partial pressures:

$$Pt = Pi + P2 + P3 + \bullet .+Pn$$

where P, is the total pressure measured, and Pr, is the partial pressure contributed by component gas n.

For the sake of simplicity, air is considered to be comprised of only two gases, nitrogen, 79% and oxygen, 21%. Thus at sea level, Dalton's law stipulates that nitrogen exerts 600 mm Hg pressure and oxygen the remaining 160 mm Hg. If one were to dive to 3 ATA and continue to breathe room air, the pressure exerted by nitrogen would be 1,800 mm Hg and the pressure from oxygen, 480 mm Hg. In contrast, placing a pa-tient in the chamber at 3 ATA and aclministering 100% oxygen would bring the pressure of oxygen to 2,280 mm Hg. The profound physiologic benefit of such a high pressure of oxygen in the plasma becomes apparent.

**TABLE 2.**
Pressure Conversion Table

| Absolute Pressures | | | Gauge Pressures | | |
|---|---|---|---|---|---|
| ATA | mm Hg | bar | fsw | psi | atm |
| 1 | 760 | 1.013 | 0 | 0.0 | 0 |
| 2 | 1,520 | 2.026 | 33 | 14.7 | 1 |
| 3 | 2,280 | 3.039 | 66 | 29.4 | 2 |
| 4 | 3,040 | 4.052 | 99 | 44.1 | 3 |
| 5 | 3,880 | 5.065 | 132 | 58.8 | 4 |
| 6 | 4,560 | 6.078 | 165 | 73.5 | 5 |

*Ahbreviations: ATA,* atmospheres absolute; *mm Hg* millimeters mercurv: *fsw,* feet of sea water; *psi,* pounds per square inch; *atm.* atmosphere.

Further explanation of the benefit of HBOT is derived from Henry's law, which refers to the increased solubility of a gas in liquid based on the pressure and a constant uniqye to each individual gas:

$$c = kP$$

The solubility of the gas, cg, is expressed as unit of volume per unit pres-sure, and Pg is the partial pressure of the gas above the liquid. If one doubles the pressure of the gas, it will double the gas concentration in solution. The solubility coefficient, k, is unique for each gas and is very high for carbon dioxide (0.837) and relatively low for oxygen (0.024) in water. This difference in solubility explains why patients with pulmonary shunting generally have abnormally low Po, in the presence of a normal Pco2.

Thus, as increasing pressure is exerted, gas will enter the liquid phase in increasing amounts. Conversely, the release of pressure may lead to the formation of bubbles of gas that will percolate out of the liquid. It is this same process at play in the pathogenesis of decompression sickness. Generally, this illness is caused by the formation of nitrogen bubbles, because most divers breathe compressed air when diving as deep as 130 feet of sea water. Deeper dives are administered with a combination of helium and oxygen to prevent nitrogen narcosis. Divers at 10 ATA will be able to breathe 2% oxygen with a pressure of 150 mm Hg, which is the normal pressure found at sea level. The remaining 98% of their mixture is helium, which is far less soluble than nitrogen, and presents less risk for bubble formation on surfacing.

The dimensions of gas bubbles that form are governed by Boyle's law:

$$PxV=K$$

The symbol, P, is pressure exerted by the gas, V is the volume it occupies, and K is a constant that depends on temperature and the number of atoms present. Thus, as pressure decreases, volume increases in this inverse relationship. Because gas bubbles form spheres, the volume is 4/37rr3. As pressure decreases from 6 to 3 atm, a small change occurs in volume with a proportionally small change in radius (r). As one goes from 3 to 1 atm, however, a profound change in volume occurs while radius changes only slightly. Thus, patients with gas embolism respond in two ways to hyperbaric oxygen therapy. The increase in pressure to 3 atm reduces the volume of bubbles to one third. The administration of oxygen also serves to displace the nitrogen out of the tissues and allows it to be expired, diminishing the risk of repeat bubble formation during decompression.

Similar principles apply to patients with medical devices, such as cuffed endotracheal tubes and colostomy bags. \Vhereas liquid does not change its dimensions appreciably with pressure fluctuation, gases do,and the cuff in the endotracheal tube needs to be deflated and reinflated with liquid, such as saline. The gas phase in a colostomy bag also needs to be expressed to prevent rupture during decompression. Rigid, glass IV bottles can implode if a sufficient volume of liquid has been replaced by air, thus plastic IV bags must be used. Similarly, during decompression if patients hold their breath they can develop severe pulmonary barotrauma, leading to pneumothorax or cerebral arterial gas embolism. Also, the gastric bubble can distend so that, if the patient has a nasogastric tube, it should be vented during decompression.

Because temperature is diiectly proportional to pressure, increasing the pressure in a chamber will increase the ambient temperature the patient experiences and decompression will lead to a sensation of cooling. All of these various laws including Charles' law can be summarized by the ideal gas law:

$$PV = nRT$$

where pressure is represented by P, V is the volume of the gas, n is the number of molecules present in moles, R is the ideal gas constant 1.38 X 10' J/kg and T is the temperature measured on the absolute scale.

The compression that occurs with hyperbaric treatment can produce barotrauma to the ears. The eustachian tubes are responsible for allowing pressure to equilibrate on both sides of the tympanic membrane. When occlusion of the intraoral stoma of the eustachian tube occurs, a pressure gradient can develop between the outside air and middle ear, across the tympanic membrane. During compression, the increase in external pressure may serve to occlude the intraoral stoma of the eustachian tube,

preventing pressure from entering the tube and leading to a lower pressure inside the middle ear than outside. Because the middle ear is primarily bony, and not compressible, the tympanic membrane will be compressed during pressurization and drawn inward. This pressure can rupture the ear drum and may even damage the round or oval windows. Separation of the round or oval window from the cochlea can lead to perilymphatic fistula. Barotrauma is less common during decompression, because the eustachian tube will generally release pressure readily from the middle ear, as the gradient favors outward movement of air from the tube. In Bither case, patients who are unable to equilibrate the pressure differential across their eustachian tubes with standard maneuvers may require myringotomy tubes.

C**ongested sinuses also may be painfully** compressed as can a gas-filled area underneath a dental filling. When divers descend without exhaling into their masks, shrinkage in the mask's air space can occur and may result in nasal hemorrhage, subconjunctival hemorrhage, and periorbital ecchymosis. Air pockets beneath hard contact (nondiffusible) lenses can also cause corneal injury. Finally, divers who descend and hold their breath can develop dramatic decreases in residual lung volume leading to hemoptysis, cough, and pulmonary edema.

Barotrauma can also occur during the ascent phase. With ascent, the middle ear can develop overpressurization resulting in vertigo. More importantly, a diver who surfaces with a full breath of air can develop pulmonary overdistention and alveolar rupture. This can lead to pneumomediastinum, pneumopericardium, pneumothorax, pneumoperitoneum, subcutaneous emphysema, or arterial gas embolism. Embolism is manifested as acute neurologic change after surfacing, such as dysfunction or sudden collapse, and should always be considered when evaluating patients in this circumstance. Much of barotrauma can be prevented by gradual descent and ascent, and many symptoms such as arterial gas embolism can be treated by immediate recompression.

## OXYGEN PHYSIOLOGY

Most of the oxygen loaded into the blood from the alveoli is carried by hemoglobin, because the solubility of oxygen is such that only 0.3 mL of 02 can be dissolved directly into the plasma component of 100 mL of blood. The same 100 mL of blood can carry approximately 20 mL of 0, in the usual 15 gm of hemoglobin found in a healthy adult. Increasing the pressure and concentration of oxygen causes a large amount of 02 to be dissolved in the plasma, according to Henry's law. At 3 ATA, the amount of oxygen dissolved in plasma can theoretically approach 2,240 mm Hg or 6.6 mL of 02 per 100 mL of blood. Because tissues generally extract 5.8mL of 02 per 100 mL for baseline metabolism, the 6.6mL of 02 dissolved in the plasma can supplant oxyhemoglobin. The ability of this treatment to sustain life was demonstrated by Boerema in 1960[9] when he substituted lactated Ringer's solution for blood in young pigs that survived in the hyperbaric chamber.

Unfortunately, administering high concentrations of oxygen has toxic side effects. The central nervous system can develop seizures, first described by Bert[7] and subsequently named the Paul-Bert effect. Similarly, pulmonary toxicity occurs with prolonged exposure to high concentrations of oxygen. This toxicity is named after Lorraine-Smith.[19] The oxygen toxicity is observed once the concentration goes above 40%, increasing steeply after 60%. Effects from pure $0_2$ can be noted as early as 6 hours after initiation, with substernal pain and tracheitis developing initially, and progressing to alveolar capillary leak at 17 hours and decreased surfactant at 24 hours. In current clinical practice, HBO is delivered intermittently, such that sufficient time is allowed for the lung to recover from high oxygen concentration exposure, and to reverse the microatalectasis that occurred from nitrogen absorption during treatment.

With increased pressure, oxygen toxicity occurs much more rapidly. Seizures will precede pulmonary dysfunction and can occur as quickly as 3 hours after being placed at 3 ATA. For this reason, most clinical protocols limit treatment at 3 ATA to 90 minutes and 2 ATA to 120 minutes.' Seizures are a dreaded complication, but there are also other less severe symptoms, such as nausea, muscular twitching, dizziness, visual disturbances, restlessness, numbness, paresthesias, and convulsions. Allowing a patient to breathe air during HBOT for a short period of time will lengthen the period of time before CNS toxicity occurs.

Oxygen-related seizures are seif-limiting and should not be a cause for panic. In point of fact, abrupt depressurization to gain rapid access to the seizing patient can do more harm than good by leading to severe barotrauma; this trauma is the result of the pressure gradient that can result if the patient's

seizure activity produces persistent spasm of the larynx. Prevention of oxygen toxicity is not yet fully understood; however, there is some credence given to the use of vitamin E, which is thought to act as an antioxidant,[21] although no firm scientific evidence exists. On a firm foundation, however, is the use of what is called an air break in which patients are given room air in the chamber at intermittent intervals to diminish their time of exposure to pure oxygen under pressure.'

## MECHANISMS OF ACTION

Although HBO has been in use for more than 100 years, the mechanism of action by which a therapeutic benefit is derived had been poorly understood until recently. Current understanding of the physiology of HBO indicates that the benefit is derived from both mechanical and chemical alterations in local and systemic physiology. The physiology of dissolved gases forms the foundation an which the application of HBO for disorders such as decompression sickness firmly rests. The theories underlying the use of HBO to treat gas embolism, carbon monoxide intoxication, and acute anemia all derive from similar principles of gas physics and oxygen physiology.

For example, blood and soft tissues that have developed nitrogen bubbles, which interfere with normal metabolism, will benefit from HBO. Compression, to make the bubbles smaller, and administration of high concentrations of oxygen will competitively drive the nitrogen bubbles out of the tissues and blood and into the exhaled air. The combination of high pressure recompression and replacement of all nitrogen with oxygen makes HBO the treatment of choice for both decompression sickness and arterial gas embolism. Dalton's law describes how the increased pressure serves to decrease the dimensions of whatever bubbles already ex-ist. The substitution of 100% oxygen for air, which has 80% nitrogen, favors the removal of nitrogen from the patient's bloodstream and prevents the reformation of bubbles during decompression at the completion of treatment. The diffusion of nitrogen from the bubbles in the blood out to the lung alveoli and into the exhaled air is the basis for this therapeutic benefit.

The provision of pure oxygen at high pressure leads to hyperoxygenation of the plasma and all tissues that are being perfused. At 3 ATA, 100% oxygen inhalation provides as much oxygen dissolved in the plasma as is extracted from the hemoglobin during normal circulation. Thus, hyperbaric oxygen can substitute for hemoglobin such that experimental animals have been kept alive with no hemoglobin in their circulatory system for a prolonged period of time.' Furthermore, a typical treatment for 2 hours shows lasting benefits of increased tissue oxvgenation for up to 2 hours after completion of the treatment.[23] In addition to providing oxygen in patients who are low in hemoglobin, this treatment also helps patients whose hemoglobin has been datnaged by various types of poisons, such as CO inhalation and methemoglobinemia. The benefit to patients with CO intoxication is twofold - the accelerated physical displacement of the CO from the hemoglobin, and the ability of the hyperoxygenetui plasma to carry and deliver oxygen, which carboxyhemoglobin cannot carry until it is normalized.

Beyoncl the bloodstream, the increased concentration of oxygen in the plasma enhances the diffusion of oxygen into the tissues in direct proportion to the pressure differential between the hyperoxygenated plasma and the interstitium. This pressure differential is increased by the conditions that occur during HBOT:

$$\text{Diffusion} \qquad A \bullet Cs/d \bullet MW/2$$

The pressure differential is represented by Xp, A is the area of diffusion, Cs is the solubility coefficient of the gas, d is the thickness of the diffusing membrane, and MW is the molecular weight of the gas. In conditions where diffusion is impaired by edema or perfusion is inadequate, the diffusion gradient that is enhanced by HBO will improve tissue metabolism through increased delivery of oxygen into the tissues.

Many of the other clinical applications accepted for use today, such as the treatment of burns, were determined by a combination of empiricism and serendipity, but now rest on a more scientific foundation. As our knowledge of the biology of wound healing has evolved, the role that oxygen plays is viei,ved in a more sophisticated schema. Much of the basis for acceptance of the benefit for HBO rests on the concept of oxygen acting almost as a drug when it is delivered in enhanced (pharmacologic) quantities to the wound. This understanding of the role of oxygen in wound healing is applied to several conditions, such as severe infection, chronic ulcers, reperfusion injury, crush injury, burns, radiation injury, and osteomyelitis.

The initiation of wound healing after injury occurs with thrombosis and platelet degranulation, rendering a wound ischemic, yet hypermetabolic. The cytokines and peptide growth factors that are released by the platelets and the leukocytes during inflammation trigger a series of steps including increased capillary permeability with fluid accumulation in the interstitium, chemotaxis of leukocytes and fibroblasts into the wound, phagocytosis of wound debris and contaminating organisms, angioneogenesis and synthesis of collagen and other extracellular matrix proteins. Oxygen is known to figure in several of these steps in wound healing.',[25] As the metabolism of the wound increases, the ischemia resulting from vessel injury, thrombosis, and wound edema serve to decrease wound perfusion and oxygenation when they are most critical, rendering the avaiability of oxygen a critical and potentially rate-limiting factor in wound healing.

During this period of host response, much of the effect of white blood cells on cellular debris and invasive bacteria within a wound is mediated by oxygen derived substances, such as peroxide. Accordingly, the provision of extra oxygen can enrich the function of hypoxic white cells in a healing wound. Because many bacteria are anaerobes or facultative anaerobes, the concentration of oxygen in a wound influences not only host response to infection, but also the pathogen's ability to survive in the host as weil. Hunt' demonstrated a dose-dependent ability of animals' wounds to clear bacteria that was directiv proportional to the administered concentration of oxygen. The increased delivery of oxygen enhanced host defenses against bacterial infection, almost as an antibiotic.

Knighton' showed that the combination of antibiotics and oxygen was additive for a host response to infection. This effect has been observed in the hypoxic soft tissue surrounding infected bone in osteo-myelitis.' The presence of increased oxygen appears to inhibit the release of toxins by certain organisms, such as Clostridium perfringens,29 such that it cannot release alpha toxins in the presence of the increased Po,. Several of the circulating ,loxins that do get released are inactivated by HBO.30 In addition the provision of high pressure oxygen to the wound is directly toxic to various anaerobic bacteria, which lack natural defenses to the oxygen radicals that accumulate in high levels und er these conditions.

Concomitant and interrelated with the autodebridement that occurs in a wound are the processes of angiogenesis and fibroplasia, both of which are also oxygen dependent. Knighton demonstrated31 that angiogenesis was stimulated by an oxygen gradient between the periphery of the wound and its center. Interestingly, the provision of increased oxygen serves to increase tissue Po, everywhere except in the center of the wound, suggesting that a wound uses the oxygen not just for energy metabolism, but also for processes such as hydroxylation of collagen." This requirement for excess oxygen renders the Po, of the wound to be a ratelimiting step in wound healing.'

Thus, HBO can accelerate healing of certain ischemic wounds bv providing a necessary substrate that is in short supply because of the events occurring locally in the wound during injury and repair.33 The administration of HBO has the potential to increase oxygenation in the underperfused wound, such as the diabetic foot uieer' and ischemic leg ulcer.3'. Accordingly, the healing deficit of chronically ischemic tissues can be corrected in part by HBO, because the tissues are provided with elevated oxygen tensions.37 This fosters cellular functions, such as fibroplasia and angiogenesis from the periphery of the ischemic wound toward the center, where they had been inhibited by the constant, severe hypoxia.

However, the mere elevation of arterial Po, cannot fully compensate for absolute deficiency of circulation.32 Therefore, the ischemic wound should first receive improved arterial inflow and venous outflow before initiating HBO. Such optimization may involve any combination of angiography, vascular surgery, and free tissue transfer to facilitate perfusion in the chronic wound and manipulation or surgical exploration of the failing tissue flap.

With regard to the chronic wound that persists despite optimized vasculature, the administration of HBO exposes the wound to hyperoxygenated plasma, and this enrichment of the wound perimeter creates a steeper 0, gradient between the perimeter and center, which facilitates wound neovascularization. Niinikoski38 found that low levels of oxygen administered to animals with healing wounds for prolonged periods of time led to dirninished collagen synthesis and healing. The intermittent, clinical administration of HBO actually serves to stirnulate the healing process more effectivelv by comhining periods of hypoxia with periods of hyperoxia. The periods of tissue hypoxia are

associated with the release of various stimulant factors by the macrophages resident in the wound.' During sessions of HBO, the tissue Po, is more than 100 mm Hg, which enables the substrate to synthesize collagen and develop new blood vessels toward the center of the wound.

Because the synthesis of collagen appears to require a Po, of 20 to 30 mm Hg, the success of any wound-healing treatment is contingent on establishing at least this level in the border of the healing wound. Ability to respond to HBO can thus be assessed by measuring the dermal tissue concentration of oxygen measurment (TCOM)' at the edge of the skin envelope both under room air conditions and while breathing 100% oxygen at normal atmospheric pressiire. Should this "oxygen challenge" show significant rise in tissue oxygen level from hypoxic levels (less than 30 mm Hg) generally seen in an ischemic wound while breathing 100% $0_2$, it is thought that the patient does possess the physiologic conditions necessary to respond locally (at the wound site) to centrally delivered HBO and will have a clinically noticeable improvement in the chronic wound.' A wound that measures less than 30 mm Hg of 0, on room air, and attains a level of 100 to 150 mm Hg of $O_2$ during a 100% 0, challenge, has a favorable prognosis for its ability to benefit from HBO. In addition, the TCOM can be monitored through a course of HBO treatment. When it is measured before each daily treatment session, a gradual rise will be seen at the border of the wound and will precede clinical improvement by 2 weeks. In addition, there may be a period of plateau, then an additional rise as the HBO produces a clinical effect.42 In addition, be cause ischemia is known to favor the proliferation of bacteria in a wound, it stands to reason that correction of ischemia, even on a temporary basis with HBO, will also favor wound healing by improving white blond cell function and consequently decreasing wound infection.

Similarly, the chronic wound of osteoradionecrosis is one of ischemic soft tissue and bone, which may also benefit from enriching the oxygen content of its soft tissue after radiation injury.43 This therapy is intended to correct the progressive, obliterative endarteritis that resuits from irradiation.44 Although this wound appears to be a superficial infection, osteoradionecrosis is a disease of tissue ischemia, and the wound will not repair itself in time' without HBO. In this disease HBO facilitates neoangiogenesis, and thereby facilitates autodebridement and fibroplasia. The current treatment protocol for osteoradionecrosis of the mandible involves a combined approach that interweaves HBO and surgery into the treatment regimen, each serving to complement the other.'

Such a regimen might well be applied in the treatment of other tissues with radiation necrosis, such as the pelvis,47 and head and neck region,48 traditionally, extensive surgical d6bridement and placement of a vascularized flap are considered the primary method of treatment.' In these wounds with extensive postirradiation ischemic disease, including chronic soft-tissue infection and necrosis, HBO might serve as a perioperative adjunct. Hyperbaric oxygen will facilitate wound healing by revascularizing the wound bed through its stimulation of neoangiogenesis before surgery, as well as supporting wound healing postoperatively by providing necessary substrate for healing. Furthermore, the course of preoperative HBO might help demarcate margins of **viability. there flaps was associated with a histologic pattern of lessened adherence of leukocytes to flap endothelium,'** suggesting a systemic effect on leukocyte behavior in response to HBO. This systemic effect was also seen in animals who were pretreated with HBO before reperfusion of small bowel. They showed a higher survival rate than animals treated after reperfusion or not at all with HBO.71

Thus, HBO appears to protect against reperfusion injury both regionally with modulation of the xanthine oxidase pathway and systemically through attenuation of the adherence of leukocytes to reperfused endothelium. In either case, the benefit of HBO for reperfusion injury is best provided during ischemia or immediately after during early reperfusion.71 This benefit is also thought to enhance the overall efficacy of HBO in treating gas embolism with neurologic symptoms, carbon monoxide inhalation with neurologic symptoms, burn injury with stasis in intermediate depth areas of burn injury, crush injury with increased compartment pressure, and severe soft tissue infection with high pressure swelling at the border of the wound.

## CONTRAINDICATIONS FOR USE OF HYPERBARIC OXYGEN THERAPY

The only absolute contraindication to HBOT is untreated pneumothorax. The potential for injury occurs during the decompression phase when volumes expand rapidly in the pneumothorax and can lead to a patient's demise. A properly functioning chest tube will permit HBOT to proceed, provided that the tube is never clamped. Similarly, patients can develop pneumothorax spontaneously during decompression. If pneumothorax does indeed develop, recompression to original depth will shrink the volume of the pneumothorax and provide time for medical assistance.

In addition to this absolute contraindication, there are several relative contraindications. Patients with chronic obstructive pulmonary disease (COPD) are at increased risk for spontaneous pneumothorax, because of their potential for air trapping in alveoli. In addition blebs and bullae, which can be seen on chest radiograph, are at increased risk for rupture on decompression, and it is theoretically possible for air to gain access to the vascular tree, causing systemic air embolism. Finally, the chronic elevation of $Pco_2$ associated with COPD can increase the risk of seizures due to oxygen toxicity as well as possibly leading to apnea when patients lose their hypoxic drive during exposure to hyperbaric oxygen. Patients who have pre-existing seizures should be treated with anticonvulsant medication,' especially phenobarbital. Patients with fever are also predisposed to oxygen seizures," whereas hypothermia appears to increase the latency before a seizure is triggered. Accordingly, patients who are in dire need of HBOT, such as those with gas gangrene with fever, should be treated with tepid bath, ice packing of the groin, and axillae and antipyretics.

Patients with acute viral illness may have a fulminant progression of their illness after treatment with HBO.7 In addition; the treatmentinduced edema of the upper airway makes it difficult to equalize pressure in the ears and sinuses. Patients with cancer mav be at risk for enhanced tumor growth from HBO.74 This is not yet clearlv established, but remains a relative contrainclication to treatment. Patients undergoing radiation therapy may have theirendarteritis potentiated by HB074 and generally have their HBOT deferred until 6 weeks after completion of radiation. Optic neuritis is a relative contraindication,73 because this can lead to blindness after treatment with HBO. Patients who have a history of sinus problems can develop mucus plugs, which can cause a sinus squeeze during compression or decompression. Decompression should be gradual for those patients who truly require HBO to help them reduce their risk of sinus squeeze. Patients with dental disease can develop compression deep in a filling, which is called dental squeeze. Patients wearing dentures should have them removed before entering the chamber, because of the risk to the airway if a seizure should occur. Similarly, chewing gum and food are not allowed during HBOT, because of the risk to the airway.

Other conditions include claustrophobia, which makes it difficult for a patient to enter the chamber." This can sometimes be treated with reassurance and antianxiety medication, such as diazepam. Patients who require intensive monitoring need to be treated using equipment that is low risk for sparking, because this could cause a fatal fire.73 Since HBO can alter the absorption, distribution, metabolism, and excretion of different medications, all medications should be given intravenously. Medication that must be given IM should be given at least 30 minutes before HBO treatment. Patients should avoid alcohol, because it causes an increased risk of decompression sickness from the dehydration, which occurs with alcohol consumption. Acetazolamide predisposes patients to oxygen seizures" and should be withheld if possible. Amphetamines may predispose patients to seizures and should be avoided. Inhalation anesthetic agents are hazardous due to the inherent vast changes in pressure; therefore general anesthesia should be delivered with intravenous agents when possible. Anticonvulsant medication may mask the oxygen toxicity that manifests as seizures. Hyperbaric oxygen potentiates the effect of digitalis,75 which may lead to toxicity manifested as nausea, vomiting, anorexia, and altered vision. Increased levels of epinephrine predispose patients to oxygen seizures." There is evidence that the vasoconstriction caused by HBO interferes with insulin absorption."

Lidocaine hydrochloride has been known to precipitate seizures when given in toxic doses; however, it should be safe for HBO patients when given in standard doses. Narcotics, on the other hand, can predispose patients to CO, retention and acidosis, which increases the likelihood of an oxygen

seizure. Furthermore, the vasoconstriction that occurs during HBO can delay the absorption of any narcotic given IM, thus leading to rebound analgesia after completion of HBOT. Nicotine is a stimulant, and thus it may lower seizure thresholds. More importantly, the combination of nicotine and HBO vasoconstriction together can lead to worsening of a patient's wound ischemia.[73] All patients must stop smoking or not be considered eligible for HBO treatment. Nitroprusside, on the other hand, is a vasodilator that is difficult to administer during HBOT due to the vasoconstriction that occurs from the HBO itself.' The patients who must receive nitroprusside and for whom HBO therapy is indicated must be monitored especially closely. Doxorubicin (Adriamycin) has been as-

The patients who must receive nitroprusside and for whom HBO therapy is indicated must be monitored especially closely. Doxorubicin (Adriamycin) has been associated with increased rnortality in laboratory animals.[77] Cis-platinum decreases the tensile strength of healing incisions.[78] Disulfiram (Antabuse) interferes with the production of superoxide dismutase critical in host defense against the toxicity of the high partial pressure of oxygen administered during HBO.[79]

All ointments and creams are hazardous, because of their flammable hydrocarbon content as well as causing aerosolization during the depress-surization which will adhere to the chamber and be difficult to clean. Pa-tients on supplemental oxygen have an increased risk of pulmonary oxygen toxicity, but should still be administered HBOT when clinically indicated. Steroids appear to decrease latency before oxygen seizures develop[75] and such patients may require seizure prophylaxis. Mafenide acetate cream (Sulfamylon), although very popular for burn care, will cause vasodilation in burn wounds and paradoxic accumulation of fluid with HBOT" rather than the generally observed diminution of edema seen in burn patients treated with HBOT." Patients who are hyperthyroid will be at increased risk of oxygen seizures."

## INDICATIONS FOR USE OF HBO (1997)

There are 12 conditions that are accepted indications for treatment with HBO according to the UHMS. Each of these is supported by a broad scientific basis as well as clinical experience (Table 1).

### DECOMPRESSION SICKNESS

### CEREBRAL ARTERIAL GAS EMBOLISM

### CARBON MONOXIDE POISONING

### CYANIDE POISONING

### GAS GANGRENE

Gas gangrene was originally a disease of war wounds, but is now almost exclusively found in the civilian population, occurring in 1,000 to 3,000 people per year in the United Stetes.' The main organisms responsible for this disease are clostridia species, especially C. *perfringens,* although it can be caused as well by *E. coli, Klebsiella, Bacteroides,* and anaerobic streptococci. Gas gangrene occurs after trauma in 50% of cases; however, it can also occur in any other situation associated with necrosis and vascular insufficiency or fecal contamination. Hyperbaric oxygen is beneficial because these organisms are inhibited by high tissue levels of oxygen.[29]

The disease is generally fulminant, developing as fast as 6 hours after initial trauma. The patients manifest systemic signs out of proportion to local signs with tachycardia and hypotension often being the hallmarks of this disease. Gas is seen in only approximately 40% of the cases and patients generally have little awareness of pain after cases have developed. Hemolvsis with secondary jaundice, renal shutdown, and disseminated intravascular coagulopathy have all been reported.' Gram stain of

the blood will demonstrate the characteristic gram-positive rods and once the diagnosis is made, therapy must be swift.' The hemolysis, which is so rapid, will usually stop within 30 minutes of initiation of HBOT (95) Penicillin is a critical antibiotic to be given, supplemented with clindamycin and gentamycin. In those allergic to penicillin, tetracycline, erythromycin, metronidazole, or chloramphenicol can be substituted.

In addition to slowing toxin production by bacteria, HB0 helps to delineate muscle necrosis, and the first treatment should precede surgery if possible. During the preoperative first treatment, antibiotics and fluids can be administered while correcting electrolyte imbalances and anemia. In addition, the Patient becomes a better risk for anesthesia after treatment, which is generally administered at 2.5 ATA. Experimental studies have shown no survival when animals were treated with either surgery or HBO alone.96 Antibiotics in this study led to a survival of 50% and antibiotics plus surgery showed a survival of 70%. A combination of HBO, surgery, and antibiotics demonstrates a survival of 95% in this study.

## NECROTIZING SOFT-TISSUE INFECTIONS

Similar to gas gangrene, necrotizing soft-tissue infections usually arise in ischemic tissue, especially in patients with altered host defense mechanisms, such as diabetics. The organisms noted include anaerobic streptococci, Bacteroides and Enterobacter as well as aerobic streptococci and staphylococci. Because of the variety of clinical syndromes that come under the general heading of necrotizing soft-tissue infection, it is difficult to characterize this category of illnesses. However, they are generally found to occur with necrotic subcutaneous tissue as a hallmark of the process.(97)

Crepitant, anaerobic cellulitis is confined to the skin and subcutaneous tissue. This is accompanied by a foul smelling purulent discharge. Meleney's ulcer," or progressive bacterial gangrene, almost always originates from a skin ulcer or operative site. There are few systemic symptoms or signs. Necrotizing fasciitis is a faster moving infection than Me-leney's ulcer with rapid necrosis of fascia and subcutaneous tissue. It is most common in the lower extremities, but can be found in the upper extremities, trunk, and perineum. Nonclostridial myonecrosis is a deeper infection that involves muscle as well. It is generally caused by anaerobic streptococci. Fournier99 described a gangrenous process involving the scrotum in otherwise healthy men. This disease can be spontaneous or secondary to pre-existing infection. The infection is polymicrobial and synergistic with E. coli, Streptococcus, Bacteroides, and Pseudomonas.

Clinically, one sees dehydration and electrolyte disturbances, most notably low serum calcium, as it is consumed in the fat necrosis. Gram staining is far more effective than attempting to identify the organisms on culture. The aroma of the exudate is foul smelling in sharp contrast to gas gangrene, which is generally a sweet smelling odor. Management of these infections centers on aggressive surgical debridement. Antibiotic therapy includes penicillin, clindamycin, and aminoglycosides for gas gangrene. Hyperbaric oxygen' is an adjunct to antibiotics and radical surgical d6bridement and needs to be given early to be beneficial. The reduction in edema, which occurs in the marginally viable region of the wound, may enhance survival of this area based on the enhanced perfusion with decreased edema, protection from reperfusion, and potentiating the effect of antibiotics that enter this tissue.

## CRUSH INJURY WITH ISCHEMIA (COMPARTMENT SYNDROME)

## CHRONIC WOUNDS

Patients with severe arterial insufficiency are generally best treated first with procedures that improve arterial inflow. In the absence of adequate inflow, HBO will be severely limited in efficacy. Furthermore, improvement of inflow deficits will often obviate the need for HBO. When inflow has been optimized, those patients with persistent wounds will frequently benefit from adjunctive HBO' particularly when oxygen challenge predicts a significant response. Hyperbaric oxygen elevates tissue oxygen tensions,[4] which may help a marginally perfused wound to develop more effective angiogenesis.

Randomized, controlled clinical trials have demonstrated that HBO is helpful for diabetic[101] and nondiabetic[36] leg wounds in patients with adequate arterial inflow. Roberts[102] studied the synthesis of glycosaminoglycan by fibroblasts grown in culture and treated with HBO. He observed an increase in the ratio of this matrix component to the number of cells in culture, suggesting that this change in cell metabolism may contribute to the healing enhancement observed in chronic wounds when patients receive HBO. There is no indication for HBO for decubitus ulcers, aside from support when flaps are compromised after surgical closure .[103]

## COMPROMISED FLAPS

Kernahan' noted a modest improvement in the survival of random flapscreated in pigs when they were treated with HBO. McFarlane" noted a more drarnatic improvement in flap survival and also demonstrated some survival of free grafts comprised of skin and **subcutaneous muscle.**

**Champion'' showed total survival of random skin flaps with HBO treatment, as opposed to 40% flap surface necrosis in controls. Based on these findings, Perrins17 assessed the effect of** HBO on skin graft survival in a randomized clinical triel, demonstrating increased skin graft survival with HBO.

The soft-tissue flap with compromised venous outflow or prolonged ischemic insult has been treated with adjunctive HBO in a number of clinical case reports.107. 1" The rationale for the addition of HBO is based on the effect on the edema of the flap. The vasospasm that occurs in response to HBO serves to decrease the inflow into the flap and helps the edema resolve.108 In addition the administration of HBO appears to decrease reperfusion injury." Laboratory studies confirm this benefit and indicate that the white blood cells are less adherent to the damaged endothelium,' with an attenuation of the entire ischemia-reperfusion cascade.

## OSTEOMYELITIS

## RADIATION NECROSIS

Most injuries involving exposure to radiation are iatrogenic, secondary to treatment for malignancy. The common pathway among most of these injuries is a proliferative endarteritis leading to a chronic nonhealing wound in the region of injury.44 Osteoradionecrosis (ORN) is a radiation induced progressive deterioration of bone. As the blood vessels become damaged in the surrounding area, the soft tissue can no longer support the metabolism of the adjacent bone and it too deteriorates. Osteoradionecrosis more closely resembles aseptic necrosis than it does osteomyelitis. The bacteria that are recovered on culture appear to be surface contaminants.

Ninety-eight percent of ORN cases involve the mandible, although they can occur on the skull or facial bones. The disease most commonly occurs after minor trauma or surgery that takes place at least 6 weeks after completion of radiotherapy. It can also occur if radiation is begun before a wound is completely healed or surgery is performed during radiation. When it becomes established, ORN is difficult to treat because of the impairment in regional circulation, which renders the wound incapable of healing.

Surgical resection merely enlarges the site of trauma and compounds the problem. Hyperbaric oxygen' has been used both preoperativelv and postoperatively with a much greater eure rate. As in osteomvelitis, the HBO itself is not effective and must be combined with debridement, antibiotics, and soft tissue reconstruction. The less severe the inciting trauma, which produces the disease, the more severe the ORN tends to be. Again, the rationale for HBO' rests on its ability to support angiogenesis at the margin of the wound as it becomes better oxygenated during treatment. The oxygen level rises to 80% to 85% normal within approximately 20 treatments and has been shown to persist alter 3 years of follow-up.

The protocol for established ORN has been developed by Marx' and is a widely accepted regimen. Hyperbaric oxygen should be considered before tooth extraction in those patients who have received radiation therapy in the past in an effort to prevent ORN. This regimen is only 95% effective in preventing ORN,116 but the 5% occurrence rate is superior to the 30% rate seen in patients given only penicillin preoperatively.

## ANEMIA

## SEI.ECTED FUNGAL INFECTIONS

## BURNS

The interest in hyperbaric oxygen for burn patient care rests on twoknown properties of this modality. The vasoconstriction that is seen withHBOT' is thought to diminish fluid extraposation and edema within the wounds,' as indicated by lessened fluid requirements during the initial resuscitation phase.' In addition, HBOT appears to decrease white blood cellmediated capillary bed injury," further decreasing tissue edema and associated tissue eschemia. On this basis, HBOT has been believed to attenuate theusual progression of superficial burns into deeper wounds by preventing stasis and sludging in the injured dermal capillary beds.12° Furthermore, HBO appears to facilitate the angiogenesis and re-epithelialization that play a z.ole in this spontaneous healing of partialthickness burns."

The prevention of burn depth progression" will not only shorten hospital stay, but will lead to higher quality burn scars and a better quality of life for patients who survive these injuries. Although there are no large scale, randomized trials available, studies(121, 122) have reported decreased length of hospital stay in burn patients treated with HBO early in their care. As with all treatments of HBO, the

sooner the treatment is begun the better; generally, it should begin within 6 hours, especially in patients with carbon monoxide poisoning.

The topical agent used should be sulfadiazine rather than mafenide acetate cream since the latter causes vasodilation that negates the effect of HBO an the wound. Furthermore, the use of narcotic analgesics needs to be carefully monitored in burn patients who undergo HBO in order to avoid respiratory depression while patients are in the chamber.

## ESTABLISHING A HYPERBARIC OXYGEN CENTER

## REFERENCES


1. Henshaw NA, Simpson A: Co'inpressed Air as a Therapeutic Agent in the Treatment of Consumption, Asthma, Chronic Bronchitis and Other Diseases. Sutherland and Knox, Edinburg, 1857.

2. Junod VT: Recherches physiologiciques et therapeutiques sur les effects del la compression et de la rarefaction de l'air, tant sur le corps que sur les members isoles. Rev Med Fr Etrange 3:350, 1834.

3. Fontaine JA: Emploi chirurgical de Pair comprime. Union Med Can 28:445, 1879.

4. Cunningham 0: Oxygen therapy by means of compressed air. Anesth Analg April:64-66, 1927.

5. Cunningham 0: The Cunningham. tank treatment. JAMA 90:1494-1495, 1928.

6. Triger: Memoire ser un appareil a' air comprime' pour les percement des puits de mines et autres travaux, sous eaux et dans les sables submerges. Compt R Rend 13:884, 1841.

7. Bert P: Barometric Pressure, Researches in Experimental Physiology. English translation by Hitchcock MA. Undersea and Hyperbaric Medical Society, Kensington, MD, 1979.

8. US Navy Diving Manual. NAVSEA, Flagstaff, Ariz, Best Publishing Company, 1993.

9. Boerema I, Meyne NG, Brummelkamp WK, et al: Life without blood (A study of the influence of high atmospheric pressure). J Card Surg 1:133-146, 1960.

10. Brummelkamp WK, Hogendijk J, Boerema I: Treatment of anaerobic infections (clostridial myositis) by drenching the atmospheric pressure. Surgery 49:299302, 1961.

11. Slack WK, Thomas DA, Perrins D: Hyperbaric oxygenation in chronic osteomyelitis. Lancet 1:1093-1094, 1965.

12. Attar S, Esmond WG, Cowley RA: Hyperbaric oxygenation in vascular collapse. Journal of Thorac Cardiovasc Surg 44:759-770, 1962.

13. Churchill-Davidson I: High pressure oxygenation and radiotherapy. Lancet 1:1091, 1955.

14. Sealy R: Hyperbaric oxygen in the radiation treatment of head and neck cancers. Radiother Oncol 20:755-795, 1991.

15. Wada J, Ikeda T, Kamata K, et al: Oxygen hyperbaric treatment for carbon monoxide poisoning and severe burns in coal mines (HOKUTAN-YUBARI) gas explosion. Igako, Japan 54:68, 1965.

16. Ketchum SA, Thomas AN, Hall AD: Angiographic studies of the effect of hyperbaric oxygen on burn wound revascularization. in Wada J, Iwa T (eds): Hyperbaric Medicine. Williams & Wilkins. Baltimore, 1969, pp 388-394.

17. Perrins D: Influence of hyperbaric oxygen on the survival of Split skin grafts. Lancet 1:868-871, 1967.

18. Gabb G, Robin ED: Hyperbaric oxygen. A therapy in search of diseases. Chest 92:1074-1082, 1987.

19. Lorraine-Smith J: The pathological effects due to an increase of oxygen tension in the air breathed. 1 Physiol 24:19-35, 1899.

20. Thora SR: Hyperbaric Oxygen Therapy: A Conunittee Report. Kensington, Mtl. Undersea & Hyperbaric Medical Society, 1992.

21. Ehrenkranz RA, Bonta BW, Ablow RC, et al: Amelioration of bronchopulmonary dysplasia after vitamin E administration. A preliminary report. N Engl Med 299:564-569, 1978.

22. Hendricks PL, Hall DA, Hunter WL Jr, et al: Extension of pulmonary 0, tolerance in man at 2ATA by intermittent 0, exposure. J Appl Physiol 42:593599, 1977.

23. Wells CH, Goodpasture JE, Horrigand D, et al: Tissue gas measurements during hyperbaric oxygen exposure. Proceedings of the 6th International Congress on Hyperbaric Medicine Aberdeen,

Scotland, University of Aberdeen Press, 1977, pp 118-124.

24. Niinikoski J, Rajamaki A, Kulonen E: Healing of open wounds: Effects of oxygen, disturbed blood supply and hyperemia by infrared irradiation. Acta Chir Scand 137:399, 1971.

25. Pai MP, Hunt TK: Effect of varying oxygen tension on healing of open wounds. Surg Gynecol Obstet 135:756, 1972.

26. Hunt TK, Linsey M, Grislis G, et al: The effect of differing ambient oxygen tension on wound infection. Ann Surg 181:35-39, 1975.

27. Knighton D, Halliday B, Hunt TK: Oxygen as an antibiotic: A comparison of the effects of inspired oxygen concentration and antibiotic administration on in vivo bacterial clearance. Arch Surg 121:191-195, 1986.

28. Mader J, Guckian JC, Giess DL, et al: Therapy with hyperbaric oxygen for experimental osteomyelitis due to Staphylococcus aureus in rabbits. J Infect Dis 138:312-318, 1978.

29. van Unnik AJM: Inhibition of toxin production in Clostridium perfringens in vitro by hyperbaric oxygen. Antonie Van Leeuwenhoek 31:181-186, 1965.

30. Bakker DJ: Clostridial myonecrosis, in Davis JC, Hunt TK (eds): Problem Wounds, the Role of Oxygen. Elsevier, New York, 1988, pp 153-172.

31. Knighton DR, Silver IA, Hunt TK: Regulation of wound healing angiogenesis: effect of oxygen gradients and inspired oxygen concentration. Surgery 90:262-270, 1981.

32. LeVan FB, Hunt TK: Oxygen in wound healing. Clin Plast Surg 17:463-472, 1990.

33. Hunt TK, Pai MP: The effect of varying ambient oxygen tensions on wound metabolism and collagen synthesis. Surg Gynec Obstet 135:561, 1972.

34. Cianci P, Hunt TK: Adjunctive hyperbaric oxygen therapy in treatment of diabetic foot wounds, in Levine IVLE, O'Neal LW, Bowker JH (eds): The Diabetic Foot, ed 5. St. Louis, Mo, Mosby, 1993, pp 305-319.

35. Hall A, Blaisdell FW, Thomas AN, et al: Response of ischemic leg ulcers in hyperbaric oxygen, in Brown IW Jr, Cox BG (eds): Proceedings of the Third International Conference on Hyperbaric Medicine. National Academy of Sciences—National Research Council, 1966, pp 625.

36. Hammarlund C, Sundberg T: Hyperbaric oxygen reduced size of chronic leg ulcers: A randomized double-blind study. Plast Reconstr Surg 93:829-834, 1994.

37. Sheffield PJ, Workman WT: Transcutaneous tissue oxygen monitoring in patients undergoing hyperbaric oxygen therapy, in Hutch RA (ed): Continuous Transcutaneous Blood Gas Monitoring. New York, Dekker, 1983, pp 655-660.

38. Niinikoski J: Effect of oxygen supply on wound healing and formation of experimental granulation tissue. Acta Physiol Scand Suppl 334:1-72, 1969.

39. Jenson JA, Hunt TK, Scheuenstuhl H, et al: Effect of lactate, pyruvate, and pH on secretion of angiogenesis and mitogenesis factors by macrophages. Lab Invest 54:574-578, 1986.

40. Sheffield PJ, Workman WT: Tissue oxygen measurements in patients administered normoharic and hyperbaric oxygen by mask. HBO Review 6:47-62, 1985.

41. Clarke D: Transcutaneous oximetry II: Interpretation. Presented at Proceedings: Hyperbaric Medicine 1994. University of South Caroline School of Medicine, Columhia, SC.

42. Sheffield PJ: Tissue oxygen measurements in problem wounds: The role of oxygen, in Davis JC, Hunt TK (eds): Problem Wounds: The Role of Oxygen. New York, Elsevier, 1988, pp 17-51.

43. Marx RE, Ehler WJ, Tayapongsak P, et al: Relationship of oxygen dose to angiogenesis induction in irradiated tissue. Am J Surg 160:519-524, 1990.

44. Marx RE: Osteoradionecrosis: A new concept of its pathophysiology. J Oral Maxillofac Surg 41:283-288, 1983.

45. Marx RE: Studies in the radiobiology of osteoradionecrosis and their clinical significance. Oral Surg Oral Med Oral Pathol 64:379-389, 1987.

46. Mounsey RA, Brown DH, O'Dwyer TP, et al: Role of hyperbaric oxygen therapy in the management of mandibular osteoradionecrosis. Laryngoscope 103:605-608, 1993.

47. Williams JA, Clerk D, Dennis WA, et al: The treatment of pelvic soft tissue radiation necrosis with hyperbaric oxygen. Am J Obstet Gyneco1167:412-416, 1992.

48. Greenwood TW, Gilchrist AG: Hyperbaric oxygen and wound healing in postirradiation head and neck surgery. Br J Surg 60:394-399, 1973.

49. Arnold PG, Lovich AF, Pairolero PC: Muscle flaps in irradiated wounds: An account of 100

consecutive cases. Plast Reconstr Surg 93:324-327, 1994.

50. Bird AD, Tefler AMB: Effect of hyperbaric oxygen an limb circulation. Lancet 355-356, 1965.

51. Plewes JL, Farhi LE: Peripheral circulatory responses to acute hypoxia. Undersea Biomed Res 10:123-129, 1983.

52. Bird AD, Tefler AMB: Effect of hyperbaric oxygen an limb circulation. The Lancet 1:355, 1965.

53. Strauss M, Hargens AR, Gershundi DH, et al: Delayed use of hyperbaric oxygen for treatment of a model anterior compartment syndrome. J Orthop Res 4:108-111, 1986.

54. Nylander G, Nordstrom H, Franzen L, et al: Effects of hyperbaric oxygen treatment in post-ischemic muscle (A quantitive morphological study). Scand J Plast Reconstr Surg 22:31-39, 1988.

55. Skyhar MJ, Hargens AR, Strauss MB, et al: Hyperbaric oxygen reduces edema and necrosis of skeletal muscle in compartment syndromes associated with hemorrhagic hypotension. J Bone Joint Surg Am 68-A:1218-1224, 1986.

56. Cianci P, Sato R: Adjunctive hyperbaric oxygen therapy in the treatment of thermal burns; a review. Burns 20:5-14, 1994.

57. Hart GB, O'Reilly RR, Broussard ND, et al: Treatment of burns with hyperbaric oxygen. Surg Gynecol Obstet 139:693, 1974.

58. Nui AKC, Yang C, Lee HC, et al: Burns treated with adjunctive hyperbaric oxygen therapy: A comparative study in humans. Presented at 9th International Symposium an Underwater and Hyperbaric Physiology, Undersea and Hyperbaric Medical Society, 967-976, 1987.

59. Ketchum SA, Zubrin JR, Thomas AN, et al: Effect of hyperbaric oxygen an small first, second, and third degree burns. Surg Forum 18:65-67, 1967.

60. Pang CY; Ischemia-induced reperfusion injury in muscle flaps: Pathogenesis and major source of free radicals. J Reconstr Microsurg 6:77-83, 1990.

61. May JW. Chait LA, O'Brien BM, et al: The no-reflow phenomenon in experimental free flaps. Plast Reconstr Surg 61:256, 1978.

62. Manson PN, Anthenelli RM, Im MJ, et al: The role of oxygen-free radicals in ischemic tissue injury in island skin flaps. Ann Surg 198:87-90, 1983.

63. Vedder N: Improved random flap survival with monoclonal leukocyte antibodv. Plast Reconstr Surg 93:1035-1040, 1994.

64. Manson PN, Narayan KK, Im MJ, et al: Improved survival in free skin flap transfers in rats. Surgery 99:211-214, 1986.

65. Im MJ, Shen WH, Pak CJ, et al: Effect of allopurinol on the survival of hyperemic island skin flaps. Plast Reconstr Surg 73:276-278, 1994.

66. Kaelin CM, Im MJ, Myers RAM, et al: The effects of hyperbaric oxygen on free flaps in rats. Arch Surg 125:607-609, 1990.

67. Tai YJ, Birely BC, Im MJ, et al: The use of hyperbaric oxygen for preservation of free flaps. Arm Plast Surg 28:284-287, 1992.

68. Angel MF, Im MJ, Chung H-K, et al': Effects of combined cold and hyperbaric oxygen storage on free flap survival. Microsurgery 15:648-651, 1994.

69. Zamboni WA, Roth AC, Russell RC, et al: The effect of acute hyperbaric oxygen therapy on axial pattern skin flap survival when administered during and after total ischemia. 1 Reconstr Microsurg 5:343-347, 1989.

70. Zamboni WA, Roth AC, Russell RC: Morphologic analysis of the microcirculation during reperfusion of ischemic skeletal muscle and the effect of hyperbaric oxygen. Plast Reconstr Surg 91:1110-1123, 1993.

71. Yamada T, Taguchi T, Hirata Y: The effect of hyperbaric oxygenation on ischemia-reperfusion injury of the small intestine. Transplantation Proc 26:1506-1507, 1994.

72. Fife C, Piantadosi C: Oxygen toxicity, in Problems in Respiratory Care. JB Lippencott, 1991, 4(2):150-171.

73. Kindwall EP, Goldman RW: Hyperbaric Medicine Procedures. Milwaukee, Wis, St. Lukes Medical Center, 1995.

74. Feldmeier JJ, Heimbach RD, Davolt DA, et al: Does hyperbaric oxygen have a cancer-causing or -promoting effect? A review of the pertinent literature. Undersea Hyperb Med 21:467-475, 1994.

75. Kindwall EP: The use of drugs under pressure, in Kindwall EP (ed): Hyperbaric Medicine

Practice. Flagstaff, Ariz, Best Publishing Company, 1994.

76. Clerk JM: Oxygen toxicity, in Kindwall EP (ed): Hyperbaric Medicine Practice. Flagstaff, Ariz, Best Publishing, 1994.

77. Upton PG, Yamaguchi KT, Myers S, et al: Effects of antioxidants and hyperbaric oxygen in ameliorating experimental doxorubicin skin toxicity in the rat. Cancer Treat Rep 70:503, 1986.

78. Nemiroff PM: Effects of cis-platinum and hyperbaric oxygen on wound healing in mice. Undersea Biomed Res 15(s):40A, 1988.

79. Heikkila RE, Cabbat FS, Cohen G: In vivo inhibition of superoxide dismutase in mice by diethyl-dithiocarbamate. J Biol Chem 251:2182, 1976.

80. Dukta AJ: Therapy for dysbaric central nervous system ischemia: Adjuncts to recompression, in Bennet PB, Moon RE (eds): Diving Accident Management. Kensington, Md, Undersea and Hyperbaric Medical Society Workshop #41, 1990.

81. McCallum RI, Harrison JAB: Dysbaric osteonecrosis: Aseptic necrosis of bone, in Bennet PB, Elliot DH (eds): The Physiology and Medicine of Diving. Philadelphia, WB Saunders, 1993.

82. Hart GB: Treatment of decompression illness and air embolism with hyperbaric oxygen. Aerosp Med October: 1190-1193, 1974.

83. Bitterman H, Melamed Y: Delayed hyperbaric treatment of cerebral air embolism. Isr J Med Sci 29:22-26, 1993.

84. Kales SN: Carbon monoxide intoxication. Am Fam Physician 48:1100-1104, 1993.

85. Tomaszewski CA, Thom SR: Use of hyperbaric oxygen in toxicology. Concepts and Controversies in Toxicology 12:437-459, 1994.

86. Garland H. Pearce J: Neurological complications of carbon monoxide poisoning. Q 1 Med, New Series XXXVI. 144:445-455, 1967.

87. Thom SR, Taber RL. N1endiguren I, et al: Delayed neurological sequelae following carbon monoxide poisoning. Ann of Enierg Med 23:612, 1994.

88. Eltorai I, Hart GB, Strauss MB: Osteomyelitis in the spinal cord injured: A review and a preliminary report on the use of hyperbaric oxygen therapy. Paraplegia 22:17-24, 1984.

89. Buchwald A: Cyanide toxicity. Ann Emerg Med 18:1257, 1989.

90. Way JL, End E, Sheehy MH: Effect of oxygen on cyanide intoxication. IV. Hyperbaric oxygen. Toxicol Appl Pharmacol 22:415-421, 1972.

91. Trapp WG: Massive cyanide poisoning with recovery: A boxing-day story. C.M.A. Journal 102:517, 1970.

92. Bouachour G, Harry P, Varache N, et al: Hyperbaric oxygen in massive cyanide poisoning: Case report with hemodynamic and oxygen consumption data. Presented at the Tenth International Congress on Hyperbaric Medicine, Amsterdam, 1990,100-103.

93. Anderson RA, Harland WA: Fire deaths in Glasgow area: III, The role of hydrogen cyanide. Med Sc/ Law 222:35-40, 1982.

94. Hart GB, Lamb RC, Strauss MB: Gas gangrene: A collective review. J Trauma 23:991-1000, 1983.

95. Bakker DJ: Clostridial myonecrosis, in Davis JC, Hunt TK (eds): Problem Wounds, the Role of Oxygen. New York, Elsevier Science, 1988, pp 153-172.

96. Demello FJ, Haglin JJ, Hitchcock CR: Comparative study of experimental Clostridium perfringens infection in dogs treated with antibiotics, surgery, and HBO. Surgery 73:936-941, 1973.

97. Bakker DJ: Necrotizing soft tissue infections. J Hyperb Med 2:161-168, 1987.

98. Meleney FL: Hemolytic streptococcal gangrene. Arch Surg 9:317-364, 1924.

99. Fournier JA: Gangrene foudroy on te de la verge. Med Pract 4:589-597, 1883.

100. Zamboni WA, Riseman JA, Kucan JO: Management of Fournier's gangrene and the role of hyperbaric oxygen. J Hyperb Med 5:177-186, 1990.

101. Doctor N, Pandya S, Supe A: Hyperbaric oxygen therapy in diabetic foot. J Postgrad Med 38:112-114,1992.

102. Roberts GP, Harding KG: Stimulation of glycosaminoglycan synthesis in cultured fibroblasts by hyperbaric oxygen. Br J of Dermatol 131:630-633, 1994.

103. Eltorai I: Hyperbaric oxygen in the management of pressure sores in patients with injuries to the spinal cord. J Dermatol Surg Oncol 7:737-740, 1981.

104. Kernahan DA, Zingg W, Kay CW: The effect of hyperbaric oxygen on experimental skin flaps. Plast Reconstr Surg 36:19-25, 1965.

105. McFariane RM, Wermuth RE: The use of hyperbaric oxygen to prevent necrosis in experimental pedicle flaps and composite skin grafts. Plast Reconstr Surg 37:422-430, 1966.

106. Champion WM, McSherry CK, Goulian D: Effect of hyperbaric oxygen on the survival of pedicled skin flaps. J Surg Res 7:583-586, 1967.

107. Ueda M, Kaneda T, Takahashi H, et al: Hyperbaric oxygen therapy of ischemic skin flaps: Clinical and experimental study. Presented at the 9th International Symposium on Underwater and Hyperbaric Physiology, Undersea and Hyperbaric Medical Society, 1987.

108. Nemiroff PM: Hyperbaric oxygen in skin grafts and flaps. Hyperb Med Pract 28:566-579, 1994.

109. Mader J, Brown GL, Gucklan JC: A mechanism for the amelioration by hyperbaric oxygen of experimental staphylococcal osteomyelitis in rabbits. J Infect Dis 142:915-922, 1980.

110. Davis JC: Refractory osteomyelitis, in Davis JC, Hunt TK (eds): Problem Wounds, the Role of Oxygen. New York, Elsevier Science, 1988, pp 125-142.

111. Strauss M: Chronic refractory osteomyelitis: Review and role of hyperbaric oxygen. HBO Review 1:231-256, 1980.

112. Calhoun JH, Cobos JA, Mader JT: Does hyperbaric oxygen have a place in the treatment of osteomyelitis. Orthop Clin N Am 22:467-471, 1991.

113. Esterhai JL Jr, Clark JM, Morton HE, et al: Effect of hyperbaric oxygen exposure on oxygen tension within the medullary canal in the rabbit tibial osteomyelitis model. J Orthop Res 4:330-336, 1986.

114. Kindwall EP: Hyperbaric oxygen's effect on radiation necrosis. Clin Plast Surg 20:473-483, 1993.

115. Marx RE, Johnson RP: Problem wounds in oral and maxillofacial surgery. The role of hyperbaric oxygen, in Davis JC, Hunt TK (eds): Problem Wounds. The Role of Oxygen. New York, Elsevier Science, 1988, pp 65-123.

116. Marx RE, Johnson RP, Kline SN: Prevention of osteoradionecrosis: A randomized prospective clinical trial of hyperbaric oxygen versus penicillin. JAMA 111:49-54, 1985.

117. Ferguson BJ, Mitchell TG, Moon R, et al: Adjunctive hyperbaric oxygen for treatment of rhinocerebral mucormyocosis. Rev Infect Dis 10:551-559, 1988.

118. Nylander G, Nordstrom H, Eriksson E: Effects of hyperbaric oxygen on oedema formation after a scald burn. Burns 10:193, 1984.

119. Cianci P, Lenders HW, Lee H, et al: Hyperbaric oxygen and burn fluid requirements: Observations in 16 patients with 40% to 80% TBSA burns (abstract). Undersea Biomed Res 15:14S, 1988.

120. Boykin JV, Eriksson E, Pittman RN: In vivo microcirculation of a scald burn and the progression of postburn dermal ischemia. Plast Reconstr Surg 66:191, 1980.

121. Cianci P, Lueders HW, Lee H, et al: Hyperbaric oxygen therapy reduces length of hospitalization in thermal burns. J Burn Care Rehabil 10:432-435, 1989.

122. Cianci P, Williams C, Lueders H, et al: Adjunctive hyperbaric oxygen in the treatment of thermal burns: An economic analysis. J Burn Care Rehabil 11:140-143, 1990.

123. Kindwall EP: Creating a hyperbaric oxygen treatment unit in a major medical center: A personal experience. Ann Plast Surg 29:543-549, 1992.

124. Swift PL, Turner JH, Oxer HF, et al: Myocardial hibernation identified by hyperbaric oxygen treatment and echocardiography in postinfarction patients: Comparison with exercise thallium scintigraphy. Am Heart J124:1151, 1992.

125. Nighoghossian MD, Trouillas MD, Adeleine MD, et al: Hyperbaric oxygen in the treatment of acute ischemic stroke—a double-blind pilot study. Strake 26:1369-1372, 1995.

126. Zhao LL, Davidson JD, Wu L, et al: Total reversal of hypoxic wound healing deficit by hyperbaric oxygen plus growth factors. Surg Forum 43:711-714, 1992.

127. Zamboni WA, Brown RE, Roth AC: Functional evaluation of peripheral nerve repair and the effect of hyperbaric oxygen. J Reconstr Microsurg 11:27-30, 1995.

128. Fife C, Meyer JS, Berry JM, et al: Hyperbaric oxygen and acute migraine pain: Preliminary results of a randomized blinded trial. Undersea and Hyperbaric Medical Society Annual Scientific

Meeting, Bethesda, Maryland, ABST #178, 1992

129. Hill RK: A blinded, cross-over controlled study on the use of hyperbaric oxygen in the treatment of migraine headache. Undersea and Hyperbaric Medical Society Annual Scientific Meeting, Bethesda, Maryland, ABST #177, 1992.

130. Nichter LS, Morwood DT, Williams GS, et al: Expanding the limits of composite grafting: A case report of successful nose replantation assisted by hyperbaric oxygen therapy. Plast Reconstr Surg 87:337-40, 1991.

131. Wasserteil V, Bruce S, Sessoms SL, et al: Pyoderma gangrenosum treated with hyperbaric oxygen therapy. Int j Dermatol 31:594-596, 1992.

132. Lavy A, Weisz G, Adir Y, et al: Hyperbaric oxygen for perianal Crohn's Disease. J Cl in Gastroenterol 19:202-205, 1994.

Thom SR.: Hyperbaric oxygen: its mechanisms and efficacy. Plast Reconstr Surg. 2011 Jan;127 Suppl 1:131S-141S.

Institute for Environmental Medicine and Department of Emergency Medicine, University of Pennsylvania Medical Center, Philadelphia, PA, USA. sthom@mail.med.upenn.edu

Comment in Plast Reconstr Surg. 2011 Jan;127 Suppl 1:142S-143S.

BACKGROUND: This article outlines therapeutic mechanisms of hyperbaric oxygen therapy and reviews data on its efficacy for clinical problems seen by plastic and reconstructive surgeons.

METHODS: The information in this review was obtained from the peer-reviewed medical literature.

RESULTS: Principal mechanisms of hyperbaric oxygen are based on intracellular generation of reactive species of oxygen and nitrogen. Reactive species are recognized to play a central role in cell signal transduction cascades, and the discussion will focus on these pathways. Systematic reviews and randomized clinical trials support clinical use of hyperbaric oxygen for refractory diabetic wound-healing and radiation injuries; treatment of compromised flaps and grafts and ischemia-reperfusion disorders is supported by animal studies and a small number of clinical trials, but further studies are warranted.

CONCLUSIONS: Clinical and mechanistic data support use of hyperbaric oxygen for a variety of disorders. Further work is needed to clarify clinical utility for some disorders and to hone patient selection criteria to improve cost efficacy.

PMCID: PMC3058327 [Available on 2012/1/1]
PMID: 21200283 [PubMed - indexed for MEDLINE]

CASE REPORT

# Hyperbaric oxygen ($HBO_2$) treatment for a failing facial flap

Brian F McCrary

Postgrad Med i 2007;83:e1 (http://www.postgradmedj.com/cgi/content/full/83/975/e1). doi: 10.1136/pgmj.2006.051706

Hyperbaric oxygen ($HBO_2$) is an approved treatment for 13 pathological entities. One of these indications—a failing facial flap—is presented in this case report of a traumatic wound to the face and right axilla after an unprovoked pit bull attack on a 4 year old girl. Surgical repair was started acutely but the facial flap became congested and ischaemic, indicating deterioration of the blood supply. $HBO_2$ treatments were initiated twice a day, resulting in remarkably decreased swelling and discomfort after the first treatment. Leeching was also used to assist with reduction of venous congestion in the flap. The patient was discharged 5 days later with a well perfused, mostly intact, incision with minimal tenderness. Surgical repair was required for a small area of wound dehiscence. Photographs documenting the patient's progress with $HBO_2$ are presented. A discussion of the mechanisms of action of $HBO_2$ and its beneficial effects is provided in this case.

Hyperbaric oxygen ($HBO_2$) treatment is currently recognised as an approved indication for 13 pathological entities.[1] These are conditions for which $HBO_2$ has substantial scientific support, demonstrating therapeutic benefit. One of these indications, compromised skin grafts and flaps is presented in this case report of a traumatic wound to the face of a child.

## CASE REPORT

The patient was a 4 year old girl who received multiple wounds secondary to an unprovoked pit bull attack. She sustained a large stellate laceration to the left side of her face and puncture wounds to her right axilla. There was no loss of consciousness. Her facial bones were not exposed and she did not have any fractures. She was transported to our emergency room on the date of injury, where our oral and maxillofacial surgery (OMS) department performed initial surgery about 5 hours after the original injury. The facial wound was reapproximated using a large flap with a small pedicle attachment.

During surgery her facial wound was irrigated with copious amounts of saline containing Bacitracin and debrided using a pulse-vac. Before closure, the integrity of the parotid duct was tested with a lachrymal probe. The facial wound was dressed with a non-adherent dressing and gauze sponges secured with tape. The wound at the right axilla was dressed with a non-adherent dressing and gauze in the operating room. Shortly after surgery the facial flap became very dusky and congested (fig 1). There was significant concern about the viability of the flap so the OMS surgeon requested emergency $HBO_2$ treatments to assist in salvaging the flap. The patient received 1 g Rocephin intravenously in the emergency department and tetanus prophylaxis in the operating room. She underwent surgery about 3 hours after the initial injury and was transported to the hyperbaric medicine department about 8 hours after the initial injury (5 hours after surgery). $HBO_2$ treatments were initiated within 45 minutes based upon the clinical appearance of the flap. Doppler and $TcPO_2$ testing was not available and treatment was not delayed to obtain this information.

The patient's past medical history was unremarkable, with no complaints or symptoms except for some mild seasonal allergic rhinitis before this injury. There were no contraindications to receipt of $HBO_2$ in this patient. Contraindications could have included current or past use of certain drugs associated with poor outcomes (doxorubicin, bleomycin, disulfiram, cis-platinum, or Sulfamylon), untreated pneumothorax or known malignancies.[2]

Physical examination showed a scared young girl, crying intermittently, but alert and oriented and willing to follow commands. Her pulse oximetry on room air measured 98%. The wound at the left side of her face was sutured with good wound edge approximation but was very dark and dusky in appearance, indicative of poor perfusion and venous congestion. The flap was pierced with a sterile syringe needle with resultant bleeding. The wound at her right axilla disclosed small puncture wounds with erythema and swelling but intact neurological functions at the right upper extremity.

A chest x ray examination was performed before initiating dives. This was done routinely during her admission but is usually done before initiating hyperbaric treatments to rule out a pneumothorax or air trapping in the lungs. The patient was treated for a compromised facial flap with hyperbaric oxygen twice a day for 2 days, then once more before her discharge from our facility. Our standard wound care treatment protocol was employed, using a modified US Air Force Treatment Table 9 at 2.46 atmospheres absolute (45 feet of sea water) for 90 minutes for each $HBO_2$ treatment. A slow descent to treatment depth was used to decrease the risk of barotraumas

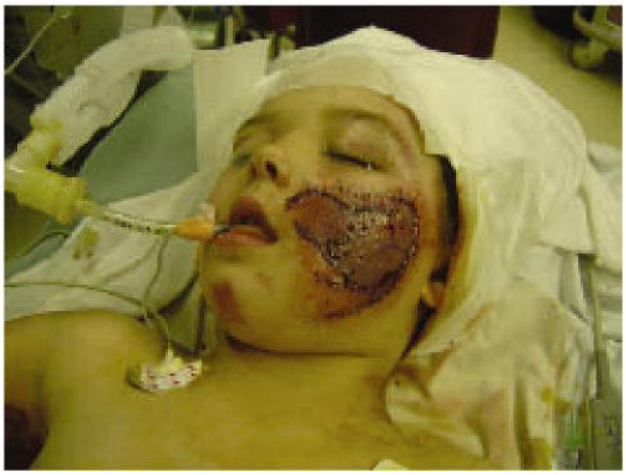

Figure 1 Failing flap before $HBO_2$. (Parental consent was given for publication of all the photographs in this paper.)

Abbreviations: $HBO_2$, hyperbaric oxygen; OMS, oral and maxillofacial surgery; PMNs, polymorphonuclear cells

Figure 2 Failing flap after first $HBO_2$ treatment.

to her ears. She did have some difficulty clearing her ears during the first treatment so she was premedicated with Afrin for subsequent treatments, with no further ear problems. The patient had significantly decreased swelling and discomfort at her face after the first treatment.

Improved tissue perfusion and improved colour were observed after the first treatment (fig 2), which continued to improve with each subsequent $HBO_2$ treatment.

The patient was placed on antibiotics prophylactically after her surgery. Leeching was used after the first $HBO_2$ treatment to assist with reduction of venous congestion. The dusky appearance of the flap suggested venous engorgement. The combination of leeching and $HBO_2$ treatments for venous occlusion has been shown to significantly improve flap survival over leeching alone.[3] This leeching was described as "special medicine"to the patient by her parents, and the leeches were covered with a cloth during these applications. Surgical debridement of her right axilla wound was done on the third day of admission.

The patient was discharged 5 days after initiating $HBO_2$ treatments, having received a total of five treatments. The incision was intact, well perfused and well approximated except for a small portion at the superior aspect which dehisced and had to be repaired surgically. There was minimal tenderness at the suture line and her facial oedema was nearly resolved. The patient continued to improve after her discharge. She was observed several weeks later and her appearance was excellent (fig 3). She was expected to undergo scar revision at some point in the future.

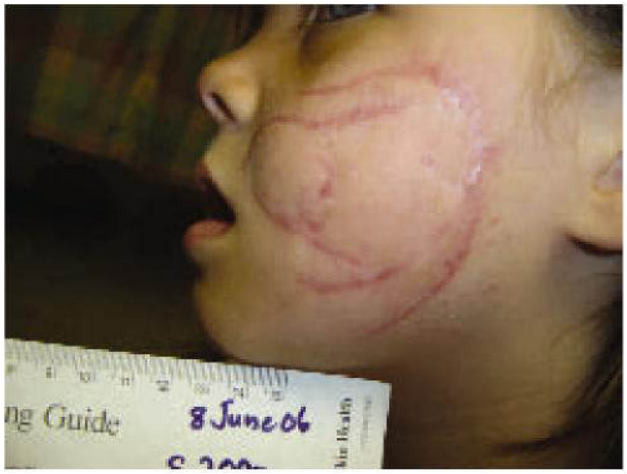


Figure 3 Healed flap.

## DISCUSSION

$HBO_2$ is neither necessary nor recommended for the support of normal, uncompromised skin grafts or flaps. However, in tissue where there is decreased perfusion or hypoxia, $HBO_2$ has been shown to be extremely useful in graft/flap salvage.[4] $HBO_2$ can help to maximise viability of the compromised tissues by counteracting trauma related tissue hypoxia and oedema and their related consequences. A number of studies have shown the efficacy of $HBO_2$ on enhancement of flap and graft survival in a variety of experimental and clinical situations.[4]

The immediate effect of $HBO_2$ is hyperoxygenation of ischaemic tissues that results from an increase in the dissolved plasma, which varies directly with the partial pressure of inhaled oxygen.[5] Hyperoxia can be of great benefit through numerous mechanisms: improvement of oxygen delivery and preservation of tissue viability in ischaemic areas,[6 7] vasoconstriction with reduction in local oedema but preservation of oxygenation,[8 9] prevention of ischaemic/reperfusion injury syndrome,[10 11] enhancement of host response to local infections,[12 13] and enhancement of the wound healing process through stimulation of angiogenesis and tissue growth and support.[14]

Injuries associated with trauma arise from ischaemia, venous outflow obstruction, tissue hypoxia, and external compression. There is a potential for self perpetuation of the injury in these cases through the reperfusion injury cascade. $HBO_2$ is an effective intervention that counteracts the pathophysiological events that occur in these conditions.

Studies show statistically significant reductions in loss of muscle function, metabolites associated with muscle injury, oedema, and muscle necrosis with use of $HBO_2$.[15] Flaps and grafts are compromised by tissue hypoxia. Studies demonstrate that flap/graft viability is enhanced by $HBO_2$ through a reduction of the hypoxic insult.[4] Other mechanisms of action whereby $HBO_2$ enhances flap survival include the enhancement of fibroblastic activity and collagen synthesis, stimulation of angiogenesis,[16 17] and possible closure of arteriovenous shunts.[18 19] $HBO_2$ also exerts favourable effects on the microcirculation, with greatly increased diffusion distance in damaged tissues and prevention of the ischaemia reperfusion injury through reduced adherence of polymorphonuclear cells (PMNs) along the venule wall. PMN adherence results in release of vasoactive substances, which can cause constriction of the adjacent arterioles.[10]

$HBO_2$ treatments for acute injuries are usually given at a pressure of 2.0–2.5 atmospheres absolute and range from 90 to 120 minutes. Initial treatments are usually done twice daily. Once the graft or flap appears more viable and stable, single daily treatments are sufficient. To be of maximum benefit, $HBO_2$ treatment should be started as soon as signs of flap compromise appear. Flap/graft viability can be assessed by clinical judgment as well as by a variety of non-invasive and invasive techniques, including transcutaneous oximetry and laser Doppler studies.[4]

Failed flaps and grafts are costly and are associated with significant morbidity to the patient.[4] This case report demonstrates that adjunctive $HBO_2$ can reduce costs and lead to a better patient outcome when flap compromise appears imminent.

Current position: Commander, Hyperbaric Medicine and Wound Care Center

The opinions, interpretations, conclusions, and recommendations are those of the authors and not necessarily endorsed by the United States Air Force.

Correspondence to: Brian F McCrary, DO, 653 Ruby Drive, Vacaville, CA 95687, USA; brian.mccrary-02@travis.af.mil

Received 21 July 2006 Accepted 25 September 2006

1 Anonymous. In:, Feldmeier JJ, ed. Hyperbaric oxygen therapy committee report. 2003: v, vi).
2 Kindwall EP. Contraindications and side effects to hyperbaric oxygen treatment. Hyperbaric medicine practice. 2nd ed revised. Flagstaff: Best Publishing Company, AZ, 2002:83–8.
3 Lozano DD, Stephenson LL, Zamboni WA. Effect of hyperbaric oxygen and medicinal leeching on survival of axial skin flaps subjected to total venous occlusion. Plast Reconstr Surg 1999;104:1029–32.
4 Zamboni WA, Shah HR. Skin grafts and flaps (compromised). In: Feldmeier JJ, ed, Hyperbaric Oxygen 2003: Committee Report. Kensington, MD: Undersea and Hyperbaric Medical Society, 2003:101–7.
5 Basset BE, Bennett PB. Introduction to the physical and physiological basis of hyperbaric therapy. In: Davis JC, Hunt TK, eds. Hyperbaric oxygen therapy. Bethesda, MD: Undersea Medical Society, 1977:11–24.
6 Nylander G, Nordstrom H, Lewis D, et al. Multiple effects of hyperbaric oxygen in postischemic muscle. Plast Reconstr Surg 1987;79:91–7.
7 Bowersox JC, Strauss MD, Hart GB. Clinical experience with hyperbaric oxygen therapy in the salvage of ischemic skin flaps and grafts. J Hyperbaric Med 1986;1:141–9.
8 Nylander G, Lewis D, Nordstrom H, et al. Reduction of postischemic edema with hyperbaric oxygen. Plast Reconstr Surg 1985;76:595–603.
9 Strauss MD, Hargens AR, Gershuni D, et al. Reduction of skeletal muscle necrosis using intermittent hyperbaric oxygen in a model of compartment syndrome. J Bone Jt Surg Am 1983;65:656–62.
10 Zamboni WA, Roth AC, Russell RC, et al. Morphological analysis of the microcirculation during reperfusion of ischemic skeletal muscle and the effect of hyperbaric oxygen. Plast Reconstr Surg 1993;91:1110–23.
11 Jordan JE, Zhao ZQ, Vinten-Johansen J. The role of neutrophils in myocardial ischemia-reperfusion injury. Cardiovasc Res 1999;43:860–78.
12 Demello FG, Haglin JJ, Hitchcock CR. Comparative study of experimental Clostridium perfringens infection in dogs treated with antibiotics, surgery and hyperbaric oxygen. Surgery 1973;73:936–41.
13 Loder RE. Hyperbaric oxygen therapy in acute trauma. Ann R Coll Surg Engl 1979;61:472–3.
14 Hunt TK, Nunikoski J, Zederfeldt BH, et al. Oxygen wound healing enhancement: cellular effects of oxygen. In: Davis JC, Hunt TK, eds. Hyperbaric oxygen therapy. Bethesda, MD: Undersea Medical Society, 1977:111–13.
15 Strauss MB. Crush injuries and skeletal muscle-compartment syndromes. In: Feldmeier JJ, eds. Hyperbaric oxygen therapy committee report 2003:27.
16 Nemiroff PM. Synergistic effects of pentoxifylline and hyperbaric oxygen on skin flaps. Arch Otolaryngol Head Neck Surg 1988;114:977–81.
17 Nemiroff PM, Rybak LP. Applications of hyperbaric oxygen for the otolaryngologist-head and neck surgeon. Am J Otolaryngol 1988;9:52–7.
18 Reinisch JF. Pathophysiology of skin flap circulation. The delay phenomenon. Plast Reconstr Surg 1974;54:585–98.
19 Reinisch JF. The role of arteriovenous anastomoses in skin flaps. In: Grabb WC, Myers MBG, eds. Skin flaps. Boston: Little, Brown, 1975:81–92.

# Hyperbaric oxygen treatment for skin flap necrosis after a mastectomy: A case study

*Joline F. Mermans M.D. [1], Stefania Tuinder M.D. [1], Maarten F. von Meyenfeldt M.D., Ph.D. [2], Rene R.W.J. van der Hulst M.D., PhD. [1]*

[1] Department of Plastic, Reconstructive and Hand Surgery, Maastricht University Medical Centre, Maastricht, Netherlands

[2] Department of Surgery, Maastricht University Medical Centre, Maastricht, Netherlands

CORRESPONDING AUTHOR: Dr. Joline Mermans – *yf.mermans@gmail.com*

**ABSTRACT**

The rate of complications in immediate breast reconstruction is in 15% to 20% due to partial loss of the mastectomy skin flaps. In the case of skin necrosis or ischemia, a therapy that reduces skin loss could be of additional benefit. Hyperbaric oxygen has been used to treat compromised flaps and grafts, an indication recognized and reimbursed according to the Undersea and Hyperbaric Medical Society (UHMS). So far, hyperbaric oxygen has not been previously reported as therapy for full-thickness breast skin flap necrosis on patients with a direct reconstruction with silicone implants after a skin-sparing mastectomy. This report presents such a case, in which a 52-year-old woman carrier of the BRCA2 mutation gene was successfully treated with hyperbaric oxygen therapy.

## INTRODUCTION

Women with an inherited BRCA2 mutations have a lifetime risk of approximately 80% and <10% for developing breast cancer or ovarian cancer, respectively [1-2]. For women already affected with breast cancer, BRCA2 mutations are associated with a 35-65% risk of developing a new primary breast cancer with a 65% risk of developing contralateral breast cancer [2]. For women who carry BRCA mutations, risk-reducing surgeries are an option to decrease breast and ovarian cancer risk. Prophylactic treatment of BRCA carriers with risk-reducing surgeries has shown greater efficacy than intensive screening or chemoprevention [3, 4]. Preventive bilateral mastectomy lowers the lifetime risk of breast cancer in BRCA carriers by more than 90%, and preventive bilateral salpingo-oophorectomy (PBSO) similarly lowers the lifetime risk of ovarian cancer in BRCA carriers by more than 90% [1, 4].

Immediate breast reconstruction after a mastectomy was introduced in the early 1980s, and skin-sparing mastectomy was introduced several years ago by Toth and lappert [5]. Despite the potential for an improved result given by immediate breast reconstruction, the complications rate is in 15% to 20%, most often due to partial loss of the mastectomy skin flap [6-8]. The thickness of the skin flaps predicts their viability. In the case of necrosis, wound healing is delayed [7, 8-10]. As a consequence, implants can be lost and skin grafting or even complete reconstruction with flap procedures (*e.g.*, latissimus dorsi flap or TRAM flap) might be required depending on the total skin loss [8]. Therefore, if necrosis or ischemia occurs, a therapy that reduces skin loss could be of additional benefit.

A number of experimental treatments have been proposed that might reduce the rate of ischemia and necrosis, including physiotherapy, hyperbaric oxygen therapy and infrared radiation. However, most treatments lack rigorous clinical investigation [9].

Hyperbaric oxygen therapy ($HBO_2T$) is defined as a treatment in which 100% oxygen is delivered to a patient at a pressure greater than two times the normal atmospheric pressure at sea level. The principle of $HBO_2T$ is based on how gases of different solubilities – most importantly oxygen – behave within tissues and fluids under changing pressure and volumes as described by Henry's, Fick's and Boyle's laws of gas behavior [11].

So far, $HBO_2T$ has not been previously reported as therapy for full-thickness breast skin flap necrosis on patients with a direct reconstruction with silicone implants after a skin sparing mastectomy. This report presents such a case, in which a woman carrier of the BRCA2 mutation gene was successfully treated with $HBO_2T$.

**FIGURE 1**

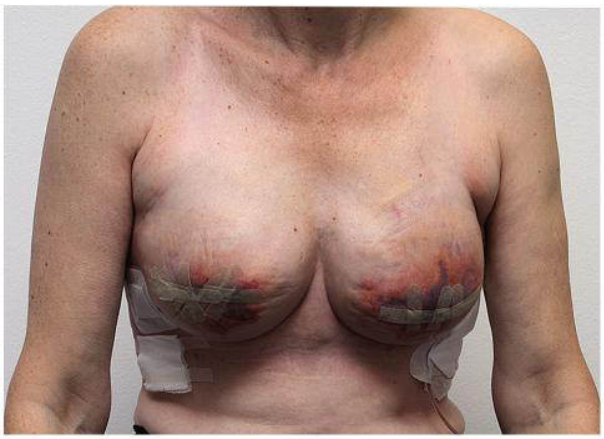

**FIGURE 2**

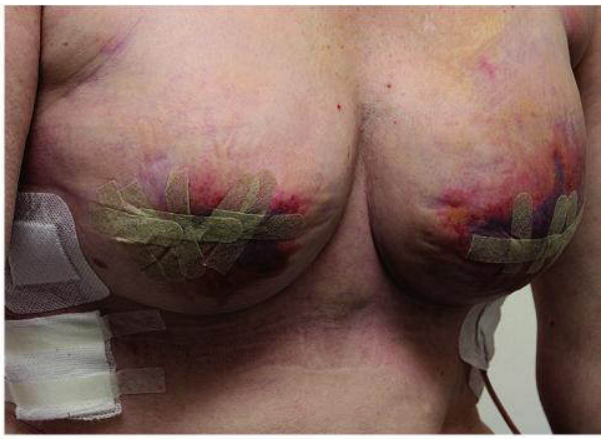

## CASE REPORT

Our patient was a 52-year-old, Caucasian woman carrier of the BRCA2 mutation gene. In 1974 she underwent an appendectomy, and in 2009 she had an uncomplicated laparoscopic adnex extirpation. The patient was a non-smoker, did not take any medications and did not have any allergies.

On breast examination no contour deformities were seen, and on palpation no dysplasia was felt. The patient had cup B with a ptosis grade 1 on Regnault classification [12]. On further examination, neither mammography nor MRI showed signs of malignancy.

After a thorough evaluation, the patient elected to undergo a prophylactic bilateral skin-sparing mastectomy with direct reconstruction with anatomic implants in November 2010

The pectoralis muscle was cleaved from lateral to medial. A sterile reconstructive tissue matrix (StratticeTM, lifeCell Corp., Somerville, N.J.) of 8x16 cm was sutured on the caudal site on the inframammary fold with vicryl 3/0 and with vicryl 3/0 on the cranial site on the pectoralis major muscle. The cavity was rinsed with Betadine solution, and anatomic silicone implants of 420 cc were inserted. Two low-vacuum drains were inserted and sutured with ethilon 3/0. The skin was closed in layers with vicryl 2/0 and vicryl 3/0 for the subcutaneous tissue and monocryl 4/0 and steristrips for the skin. The same procedure was performed on the other site. After closure there was no tension noted on either skin flap.

Post-operatively the patient received co-trimoxazole 960 mg one tablet twice daily for four days.

On postoperative day (POD) 1 the skin flaps were compromised. The patient complained of painful breasts. On examination the breasts were swollen, and erythema with breakdown was noted around both breast wounds *(Figures 1-2, above)*. There was no fever, chills or night sweats.

On POD 3 the diagnosis skin flap necrosis was assumed, and $HBO_2T$ in the hyperbaric oxygen clinic in Aachen (Germany) was initiated.

From POD 4 till POD 19, the patient was treated with 20 sessions of hyperbaric oxygen, each belonging to the Marx-scheme, *i.e.*, 3 * 30 minutes $FiO_2 = 1.0$ via a face mask under a pressure of 2.4 atmospheres absolute (atm abs). The transcutaneous measured values of oxygen ($tcpO_2$) had a range between 940 and 1160 mm mercury and were within the therapeutic range. Under therapy the patient reported no problems concerning pressurization. Nevertheless, on POD 10 after her sixth treatment the patient suffered from a hyperoxic seizure, which was treated with 5 mg midazolam. Neurological consultation in the university clinic at Aachen showed no pathological cause. In the following 14 treatments the oxygen exposure was cut off five minutes each time, with no further complications. The patient reported a good tendency of healing of the compromised tissue, so the oxygen treatment was stopped after the 20th exposure.

On POD 23 the patient was seen in the outpatient clinic of plastic surgery. On examination we observed necrotic tissue that was well marked and showed no more signs of infection. The ischemic tissue was clearly diminished 3 to 4 cm *(Figure 3, facing page)*.

**FIGURE 3**

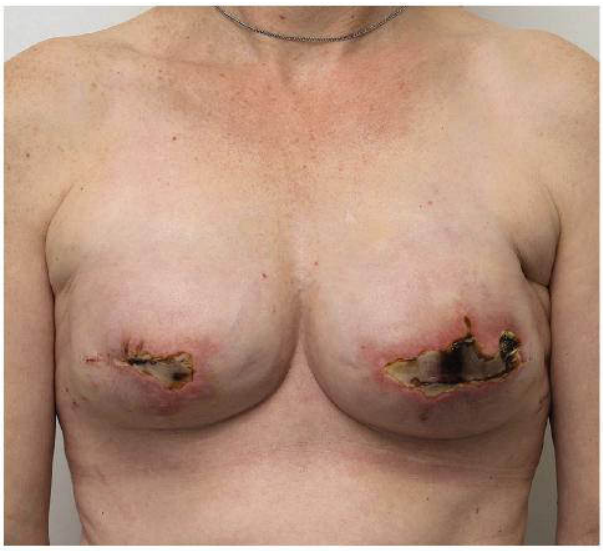

**FIGURE 4**

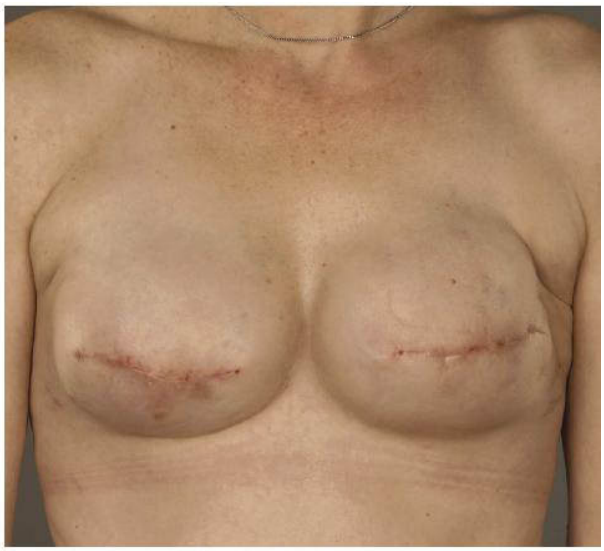

On POD 25, the patient underwent debridement of the remaining necrotic tissue on both breasts. The superficial skin necrosis extended into the mastectomy skin into the strattice layer. On the right side the skin could be closed primarily. However, on the left side the defect was too big to close primarily. The surgeons decided to place a Mentor tissue expander 350 cc on the left side, which was expanded to 200 cc. Afterwards the skin was closed in layers *(Figure 4)*.

**DISCUSSION**

Post-operatively, there was no tension on the flaps. Therefore we think that this has not contributed to the complication in our patient. A very thin skin flap left by the oncologic surgeon or a possible predisposition of the patient to develop skin flap necrosis might have caused the complication seen in our patient.

Because of the higher risk of complications after skin-sparing mastectomies, vigilant monitoring of the wound and skin flaps must be done. Hematomas should be drained, infections should be diagnosed and treated, and full-thickness skin flap necrosis should be excised expeditiously. leaving substantial amounts of necrotic skin beyond two weeks adds significantly to the risk of infection and implant extrusion [13]. In the case of our patient, we did not make the direct choice for debridement; but we chose to save some of the already-ischemic skin tissue while also preventing any possible infection by using the $HBO_2T$ technique.

$HBO_2T$ has been used to treat compromised flaps and grafts, and is an accepted indication recognized by the Undersea and Hyperbaric Medical Society (UHMS) [14-15]. Even though, the systematic review of Eskes *et al.* identified insufficient evidence to support or refute the effectiveness of $HBO_2T$ for the management of acute surgical or traumatic wound. Moreover, support for use of $HBO_2T$ in compromised flaps and grafts comes from a very large number of animal studies [16-20], support from clinical trials with a high level methodological evidence is missing [21-23]. Until this evidence is present, this specific application must rely on expert opinion and trial and error to see whether it provides significant benefits.

$HBO_2T$ use in compromised skin flaps may have mainly three effects. First, $HBO_2T$ may improve post-ischemic tissue survival. This is achieved largely through controlled and brief increases in reactive oxygen species (ROS) and reactive nitrogen species (RNS) [20, 24]. An increase of ROS and RNS causes an inhibition of B2 integrins and therefore may improve post-ischemic tissue survival. An early event associated with post-ischemic tissue reperfusion is a pathologic adherence of circulating neutrophils to the vascular endothelium by B2 integrins. In addition, the increase in ROS and RNS impairs pro-inflammatory cytokine production by monocyte-macrophages, causing diminished inflammatory responses and improving post-ischemic tissue survival [15, 24-25]. As a consequence, post ischemic infection is also prevented.

An improvement in post-tissue survival is also achieved as $HBO_2T$ corrects the amount of oxygen delivered to the wound site by increasing the blood-oxygen level within the injury and reallocating the blood flow to hypoxic areas due to a protective mechanism that causes hyperoxic vasoconstriction in the surrounding normal tissue (6, 26).

Secondly, $HBO_2T$ enhances endogenous antimicrobial activity, especially in anaerobic infections, by helping to restore tissue oxygen tension required for leukocytes to function normally with regards to oxidative-killing mechanisms [11, 15].

Finally, oxygen benefits the wound healing process as described in several studies (20-21, 24, 27-28). According to Tompach *et al.* [32], in the inflammatory stage, oxygen controls the migration and proliferation of fibroblasts. In the proliferative phase, angiogenesis also requires oxygen. Finally, in the remodeling stage, the production of collagen by fibroblasts is oxygen-dependent.

For $HBO_2T$ to have an effect on these three conditions, time of $HBO_2T$ application is of major importance. Transportation logistics and the limited availability of $HBO_2T$ facilities may preclude its use during an early phase of wound healing to counteract the ischemia and necrosis of acute surgical and traumatic wounds. Only an effect to preserve hypo-oxygenated tissue may be expected [21-22, 29]. As with the patient in this study, who was treated on POD 4, $HBO_2T$ has been used mainly for its wound healing effect and prevention of infections that could be caused by necrosis and ischemia.

Based on the previously mentioned physiologic roles of $HBO_2T$ and the role of oxygen in the wound healing process, there is a good explanation as to why this therapy worked on our patient. Our patient showed a remarkable drawback of the hypo-oxygenated tissue after just a few $HBO_2T$ sessions and did not require any skin grafting or reconstruction with flap procedures.

Also, if application of $HBO_2T$ in this particular situation would have been the standard treatment, our patient might have had more benefits from the treatment than in the current situation. In our case an operation was still needed. If application of $HBO_2T$ treatment had been done at the time of presentation of the ischemia, which was possible, as the hyperbaric oxygen clinic in Aachen (Germany) is in nearby Maastricht (Netherlands), more tissue could have been saved and the patient would not have needed an operation.

These benefits are the essence of this case report. Therefore we believe that $HBO_2T$ application should directly be considered for these wounds if costs are acceptable and if $HBO_2T$ facilities are available at the time of presentation.

## CONCLUSION

In this case report we present an unusual use of $HBO_2T$ application on compromised skin flaps. To the best of our knowledge $HBO_2T$ has not been previously reported as therapy for full-thickness breast skin flap necrosis on patients with a direct reconstruction with silicone implants after a skin-sparing mastectomy.

As $HBO_2T$ showed a positive effect on our patient, we advise that if $HBO_2T$ facilities are available at time of presentation, the benefits of the therapy should be evaluated against the adverse events in every patient.

n

## REFERENCES


1. Fatouros M, Baltoyiannis G, Roukos DH. The predominant role of surgery in the prevention and new trends in the surgical treatment of women with BRCA1/2 mutations. Ann Surg Oncol 2008;15:21-33

2. Ashikari RH, Ashikari AY, Kelemen PR, Salzberg CA. Subcutaneous mastectomy and immediate reconstruction for prevention of breast cancer for high-risk patients. Breast Cancer 2008;15:185-91.

3. Bermejo-Pérez MJ, Márquez-Calderón S, Llanos-Méndez A. Effectiveness of preventive interventions in BRCA1/2 gene mutation carriers: a systematic review. Int J Cancer 2007;121:225-231.

4. Beattie MS, Crawford B, Lin F, Vittinghoff E, Ziegler J. Uptake, time course, and predictors of risk-reducing surgeries in BRCA carriers. Genet Test Mol Biomarkers. 2009;13:51-56.

5. Toth BA, Lappert P. Modified skin incisions for mastectomy; the need for plastic surgical input in preoperative planning. Plast Reconstr Surg 1991; 87:1048-1053.

6. Radovanovic Z, Radovanovic D, Golubovic A, Ivkovic-Kapicl T, Bokorov B, Mandic A. Early complications after nipple-sparing mastectomy and immediate breast reconstruction with silicone prothesis: results of 214 procedures. Scandinavian J Surg 2010; 99:115-118.

7. Larson DL, Basir Z, Bruce T. Is oncologic safety compatible with a predictable viable mastectomy skin flap? Plas.Reconstr.Surg.2011;127:27-33.

8. Carlson GW, Bostwick III J, Styblo TM. Skin-sparing mastectomy. Oncologic and reconstructive consiferations. Ann Surg. 1997; 225 :570-575.

9. Chen J, Lv Q, Yu M. Randomized clinical trial of Chinese herbal medications to reduce wound complications after mas-tectomy for breast carcinoma. Br J Surg. 2010; 97:1798-1804.

10. Davies K, Allan L, Roblin P. Factors affecting post-operative complications following skin sparing mastectomy with immediate breast reconstruction. Breast. 2011; 20:21-25

11. Edwards ML. Hyperbaric oxygen therapy. Part 1: history and principles. J Vet Emerg crit Care 2010; 20:284-288.

12. Regnault P. Breast ptosis. Definition and treatment. Clin Plast Surg. 1976; 3:193-203

13. Spear SL, Mesbahi AN. Implants-based reconstruction. Cli Plastic Surg. 2007; 34:63-73.

14. Gesell L. Hyperbaric oxygen therapy indications. 12th ed. Durham, N.C: Undersea and Hyperbaric medical Society; 2008.

15. Edwards ML. Hyperbaric oxygen therapy. Part 2: application in disease. J Vet Emerg crit Care 2010; 20:289-297.

16. Rubin JS, Marcella L, Mayers RA. Effect of hyperbaric oxygen on the take of composite skin grafts in rabit ears. J Hyperbaric Med 1988; 3:79-88.

17. Zhang F, Cheng C, Gerlach T. Effect of hyperbaric oxygen on survival of the composite ear graft in rats. Ann Plast Surg. 1998;41:530-534.

18. McFarlane RM, Wermuth RE. The use of hyperbaric oxygen to prevent necrosis in experimental pedicle flaps and composite skin grafts. Plast Reconstr Surg. 1966;37:422-430.

19. Wald HI, Georgiade HG, Angelollo J. Effects of intensive hyperbaric oxygen therapy on the survival of experimental skin flaps in rats. Surg Forum. 1968;19:497-499.

20. Friedman HI, Fitzmaurice M, Lefaivre JF, Vecchiolla T, Clarke D. An evidence-based appraisal of the use of hyperbaric oxygen on flaps and grafts. Plast Reconstr Surg. 2006;117: 175S-190S. Eskes AM, Ubbink DT, Lubbers MJ, Lucas C,

Vermeulen H. Hyperbaric oxygen therapy: solution for difficult to heal acute wounds? Systematic review. World J Surg. 2011; 35:535-542.

21. Eskes A, Ubbink DT, Lubbers M, Lucas C, Vermeulen H. Hyperbaric oxygen therapy for treating acute surgical and traumatic wounds. Cochrane Database Syst Rev. 2010; 6;(10):CD008059.

22. Roje Z, Roje Z, Eterović D, et.al. Influences of adjuvant hyperbaric oxygen therapy on short-term complications during surgical reconstruction of upper and lower extremity war injuries: retrospective cohort study. Croat Med J. 2008; 49:224-232.

23. Thom SR. Hyperbaric oxygen: its mechanisms and efficacy. Reconstr. Surg.2011; 127:131S-141S.

24. Fife CE, Hopf H. Discussion: Hyperbaric oxygen: its mechanisms and efficacy. Reconstr. Surg. 2011;127:142S-143S.

25. Thackham JA, McElwain DL, Long RJ. The use of hyperbaric oxygen therapy to treat chronic wounds: A review. Wound rep Reg 2008;16:321-330.

26. Rodriguez PG, Felix FN, Woodley DT, Shim EK. The role of oxygen in wound healing: A review of the literature. Dermatol Surg 2008; 34:1159-1169.

27. Roje Z, Roje Z, Janković S, Ninković M. Breast reconstruction after mastectomy. Coll Antropol. 2010;34: 113-123.

28. Bertoletto PR, Chaves JC, Fagundes AT, Simões RS, Oshima CT, Simões Mde J, Fagundes DJ. Effect of different periods of hyperbaric oxygen on ischemia-reperfusion injury of rat small bowel. Acta Cir Bras. 2008; 23:11-15.

29. Zamboni WA, Browder LK, Martinez J. Hyperbaric oxygen and wound healing. Clin Plastic Surg. 2003;30:67-75.

30. Wang C, Schwaitzberg S, Berliner E, Zarin DA, Lau J. Hyperbaric oxygen for treating wounds. A systematic review of the literature. Arch Surg. 2003;138:272-279.

31. Tompach PC, Lew D, Stoll JL. Cell response to hyperbaric oxygen treatment. Int J Oral Maxillofac Surg 1997; 26:82-86.

Byrne JB, Egnaczak S, Pons P, McCaffrey J : HYPERBARIC OXYGEN FOR SALVAGE OF BELOW-KNEE AND TRANS-METATARSAL AMPUTATION FLAPS *UHM 2008, Vol. 35, No. 4 — Abstracts from UHMS ASU 2008.*

St. Joseph's Hospital Center for Wound Care and Hyperbaric Oxygen. Syracuse, NY

**BACKGROUND:** Hyperbaric oxygen (HBO) has been widely used to salvage ischemic surgical flaps. However, there are no randomized clinical trials in the literature to support this practice, and it appears unlikely that these studies will ever be done for ethical reasons. Therefore, we feit it would useful to retrospectively review our experience in a wound care center with the use of HBO to salvage below-knee (BKA) and trans-metatarsal (TMA) amputation flaps. Our main focus was to assess the efficacy of salvage of BKA and TMA flaps, thus avoiding amputation at a higher level.

**METHODS:** Our wound care center treated 7 patients with 8 failed BKA or TMA flaps over a three-year period. There were 3 BKA failures (two in the same patient) and 5 TMA failures. Amputation failure presented as dehiscence and/or necrosis of the amputation flaps. Six of the 7 patients were diabetics, and 2 had chronic renal failure requiring dialysis. All patients were treated with HBO at 2 ATA for 120 minutes daily, 5 days per week. The number of HBO treatments per patient ranged from 23 to 40, with an average of 35.

**RESULTS:** Following treatment with HBO, 4 of the 5 failed TMA flaps healed completely and 1 TMA flap improved to the point that the remaining wound was only 1 cm in length. That TMA flap has remained stable for 2 and Vz years. 2 of the 3 BKA flaps healed completely. The one flap that failed HBO was a BKA with an exposed portion of the fibula. This was the only patient in the series that failed HBO and required a higher amputation, in this case to the AKA level.

**CONCLUSIONS:** In our experience, HBO has been an effective Intervention for necrotic and/or dehisced BKA or TMA flaps. The avoidance of higher amputation in 7 out of 8 cases demonstrates both the clinical and cost effectiveness of HBO in this setting

PIPER SM, LEGROS TL, MURPHY-LAVOIE H, HARCH PG: SALVAGE OF A COMPROMKSED FLAP AND GRAFF UTILIZING HYPERBARIC OXYGEN THERAPY IN A SEVERELY COMPROMISED HOMELESS PATIENT. UHM 2011, VOL. 38, NO. 5 — ABSTRACTS: HBO2 THERAPY AND CELLULAR MECHANISMS

Louisiana State University Health Sciences Center Undersea and Hyperbaric Medicine Fellowship Program, Harvey, La

**Introduction / Background:**
A 54-year-old African American male presented to the emergency department with three weeks of dominant right hand pain due to an auto-pedestrian accident. Co-morbidities included homelessness, paranoid schizophrenia, malnutrition, tobacco abuse and alcohol abuse. He was admitted with diagnosis of right hand flexor tenosynovitis and cellulitis. He remained hospitalized for three weeks and was treated with intravenous antibiotics, multiple incision and drainage procedures, wound vacuum therapy, reverse radial forearm flap and split thickness autogenous skin graft. He followed up with the hyperbaric medicine service two days after discharge, with no evidence of infection or flap/graft compromise and was treated with routine wound care. He returned two weeks later with a grossly edematous hand, separating purulent necrotic flap, and partially necrosed weeping skin graft.
**Materials and methods:**
He received 24 daily 90-minute HBO2T sessions over seven weeks: two at 2.0 ATA and 22 at 2.4 ATA. He was counseled regarding the importance of nutrition and the arm was elevated with a sling. Routine wound care, including debridement, was performed.
**Results:**
The compromised flap and graft responded with sloughing of a 2.5-cm segment of skin and apparent salvage of his dominant hand. No further surgical intervention was required.
**Summary/Conclusions:**
The patient had multiple co-morbidities and compromising factors that were responsible for his failing flap and graft. Due to his paranoid schizophrenia and social circumstances, wound care and HBO2T were the only therapies that we were able to deliver. HBO2T in compromised flaps and grafts is able to increase oxygenation, reduce oedema, increase capillary growth, inhibit infection, and stimulate growth of new tissue. All of these processes contributed to the salvage of the patient's dominant hand even in the absence of correction of other co-morbidities and compromising host factors and even when therapy was significantly delayed

Bennett MH, Feldmeier J, Hampson N, Smee R, Milross C.: Hyperbaric oxygen therapy for **late radiation tissue injury**. **Cochrane Database** Syst Rev. 2005 Jul 20;(3):CD005005 Cochrane Database Syst Rev. **2012;**5:CD005005.

Department of Diving and Hyperbaric Medicine, Prince of Wales Hospital, Barker Street, Randwick, New South Wales, Australia, 2031. m.bennett@unsw.edu.au

BACKGROUND: Cancer is a significant global health problem. Radiotherapy is a treatment for many cancers and about 50% of patients having radiotherapy with be long-term survivors. Some will experience LRTI developing months or years later. HBOT has been suggested for LRTI based upon the ability to improve the blood supply to these tissues. It is postulated that HBOT may result in both healing of tissues and the prevention of problems following surgery.

OBJECTIVES: To assess the benefits and harms of HBOT for treating or preventing LRTI.

SEARCH STRATEGY: We searched The Cochrane Central Register of Controlled Trials

(CENTRAL) Issue 3, 2004, MEDLINE, EMBASE, CINAHL and DORCTHIM (hyperbaric RCT register) in September 2004.

SELECTION CRITERIA: Randomised controlled trials (RCTs) comparing the effect of HBOT versus no HBOT on LRTI prevention or healing.

DATA COLLECTION AND ANALYSIS: Three reviewers independently evaluated the quality of the relevant trials using the guidelines of the Cochrane Handbook Clarke 2003) and extracted the data from the included trials.

MAIN RESULTS: Six trials contributed to this review (447 participants). For pooled analyses, investigation of heterogeneity suggested important variability between trials. From single studies there was a significantly improved chance of healing following HBOT for radiation proctitis (relative risk (RR) 2.7, 95% confidence Interval (CI) 1.2 to 6.0, P = 0.02, numbers needed to treat (NNT) = 3), and following both surgical flaps (RR 8.7, 95% CI 2.7 to 27.5, P = 0.0002, NNT = 4) and hemimandibulectomy (RR 1.4, 95% CI 1.1 to 1.8, P = 0.001, NNT = 5). There was also a significantly improved probability of healing irradiated tooth sockets following dental extraction (RR 1.4, 95% CI 1.1 to 1.7, P = 0.009, NNT = 4). There was no evidence of benefit in clinical outcomes with established radiation injury to neural tissue, and no data reported on the use of HBOT to treat other manifestations of LRTI. These trials did not report adverse effects.

AUTHORS' CONCLUSIONS: These small trials suggest that for people with LRTI affecting tissues of the head, neck, anus and rectum, HBOT is associated with improved outcome. HBOT also appears to reduce the chance of osteoradionecrosis following tooth extraction in an irradiated field. There was no such evidence of any important clinical effect on neurological tissues. The application of HBOT to selected patients and tissues may be justified. Further research is required to establish the optimum patient selection and timing of any therapy. An economic evaluation should be also be undertaken. There is no useful information from this review regarding the efficacy or effectiveness of HBOT for other tissues.

PMID: 16034961 [PubMed - indexed for MEDLINE]

Iorio ML, Endara M, Desman E, Fontana L, Attinger C.: Occult radiation injury following angiographic procedures: recognition and treatment of an evolving complication. Ann Plast Surg. 2011 Aug;67(2):109-13.

Department of Plastic Surgery, Center for Wound Healing, Georgetown University Hospital, Washington, DC, USA.

As the indications for fluoroscopically guided procedures increase, so do the potential complications from radiation. **Radiation-induced wounds** can have an insidious onset and time course that the plastic surgeon and wound specialist must be able to identify early. We review 3 cases of radiation-induced wounds following fluoroscopic procedures, which presented at various stages of diagnosis and healing. The pathophysiology of these wounds is discussed to aid in their diagnosis by providing an understanding of the resultant time course of injury and characteristics of the wounds. In addition, a familiarity of the concepts of interventional procedures and an increased element of caution in those patients most susceptible to injury is critical for prevention. Finally, an appropriate treatment protocol is proposed including early diagnosis, local wound care, hyperbaric oxygen, en bloc resection of the affected tissue, and reconstruction with tissue outside the zone of injury for recalcitrant or late stage wounds.

PMID: 21346526 [PubMed - in process]

Shoshani 0; Shupak A; Ullmann Y; Ramon Y; Gilhar A; Kehat I; Peled IJ.: The effect of hyperbaric oxygenation on the viability of human fat injected into nude mice. Plastic and reconstructive surgery 2000 Nov; 106 (6), pp. 139066; discussion 1397-8.

"Histopathotogic examination of the dissected grafts demonstrated a significantly better integrity of the fat tissue in the group that received hyperbaric oxygen for 5 days (p 0.047). This finding was manifested by the presence of well-organized. intact fat cells, along with a normal appearance of the fibrous septa and blond vessels."

---

Cantarella G, Mazzola RF, Pagani D: The fate of an amputated nose after replantation. Am J Otolaryngol. 2005 Sep-Oct;26(5):344-7.

Department of Otolaryngology, Fondazione IRCCS Ospedale Maggiore Policlinico, Mangiagalli e Regina Elenza, Milano, Italy. giovanna.cantarella@policlinico.mi.it

Traumatic amputation of the nose is a challenging management problem. We describe the **case** of a 69-year-old woman who had a dog-bite nasal amputation. The avulsed piece, including the lobule, and approximately half of the columella and alae, was replanted within 2 hours of the trauma. **Hyperbaric oxygen therapy was administered for 12 daily** sessions. Skin gradually necrosed, and the scar was tangentially excised. Almost all of the mucosa and of the cartilage layers survived and the final defect was smaller than the original. A 3-stage repair was performed by a paramedian forehead flap to replace cover. Lining was by approximation of native tissues, whereas framework was reinforced by conchal and septal cartilage grafts. The outcome was functionally and aesthetically satisfactory.

Our case confirms that replantation of an amputated nose as a composite graft is worthwhile. Although the skin necrosed and required reconstruction, most of the lining and of the cartilage support survived, greatly improving the ease of reconstruction, as well as nasal function.

PMID: 16137535 [PubMed - indexed for MEDLINE]

Al-Waili NS, Butler GJ, Petrillo RL, Carrey Z, Hamilton RW.: Hyperbaric oxygen and lymphoid system function: a review supporting possible intervention in tissue transplantation. Technol Health Care. 2006;14(6):489-98.

Life Support Technology Group and NEW Technology, Inc, The Mount Vernon Hospital, Sound Shore Health System, Mount Vernon, NY 10550, USA. noori786@yahoo.com

This review addresses the many ways that hyperbaric oxygen (HBO2) has been found to mitigate immune reactions, many of which are involved in rejection of allograft transplants, and thus offers a rationale for its possible use as an adjunct to help preserve and protect transplanted tissues.
Rejection may involve both immunological reactions of the lymphoid system, or lymphoid-independent damage from trauma or other factors, including reperfusion injury. Lymphoid-induced damage involves cellular elements such as CD4 and macrophage cell types, as well as both pro inflammatory and inhibitory cytokines. Cytokines such as TNFs and interleukins activate T-cells and macrophages, resulting in endothelial damage and its consequences. The immunosuppressive effects of HBO2 include suppression of autoimmune symptoms, decreased production of IL-1 and CD4 cells, and increased percentage and absolute number of CD8 cells. HBO2 normalizes cell-bound immunity and decreases the serum concentration of immune complexes. Studies have shown MHC class I expression to be altered when cultures were exposed to HBO2, so as to become undetectable by monoclonal antibodies or cytotoxic T lymphocytes.
HBO2 has been used in support of replanted rabbit ear grafts, spinal cord tissue transplants, dislocated young permanent teeth in children, replanting of fingers, free fibula reconstruction of segmental mandibular resections, autogenous free bone grafts, transplantations of the cornea, and liver transplants. In addition to its specific effects on the immune system, HBO2 improves tissue oxygenation, reduces free radical damage during reperfusion, maintains marginally ischemic tissue, and accelerates wound healing. These properties make HBO2 a promising intervention to be tested in transplantation recipients.

PMID: 17148861 [PubMed - indexed for MEDLINE]

Li EN, Menon NG, Rodriguez ED, Norkunas M, Rosenthal RE, Goldberg NH, Silverman RP.: The effect of hyperbaric oxygen therapy on composite graft survival. Ann Plast Surg. 2004 Aug;53(2):141-5.

Division of Plastic and Reconstructive Surgery, University of Maryland Medical Systems, Baltimore, MD, USA.

Auricular composite grafts are a useful reconstructive option, particularly for nasal reconstruction. This study evaluates the effect of hyperbaric oxygen (HBO) therapy on auricular composite graft survival in **rabbits**. Circular chondrocutaneous composite grafts of 0.5, 1, or 2 cm in diameter were resected from the ears of rabbits. The grafts were sutured back into position. Half the rabbits in each group received HBO postoperatively, consisting of 90 minutes at 2.4 atm. Rabbits received 7 treatments in 5 days. Control rabbits did not receive HBO. On day 21 the percentage area of graft survival was calculated from gross and histologic examination.

Two-centimeter grafts treated with HBO (n = 8) had a mean graft survival rate of 85.8 +/- 15.7% compared with a survival rate of 51.31 +/- 38.5% for the control group (n = 8; P = 0.0478). There was no such benefit in smaller grafts.

HBO could prove clinically useful for larger composite grafts.

PMID: 15269583 [PubMed - indexed for MEDLINE]

Gungor A, Poyrazoglu E, Cincik H, Sali M, Candan H, Ay H.: The effectiveness of hyperbaric oxygen treatment in tracheal reconstruction with auricular cartilage grafts (experimental study). Am J Otolaryngol. 2003 Nov-Dec;24(6):390-4.

Department of ENT, Gulhane Military Medical Academy, Haydarpasa Training Hospital, Istanbul, Turkey. atilagungor@superonline.com

Erratum in: Am J Otolaryngol. 2005 Mar-Apr;26(2):150. Ay, Hakan [added].

PURPOSE: Tracheal stenosis or neoplastic changes, as well as, traumatic, congenital, or iatrogenic causes may require extensive tracheal resections. Complications like vascularization insufficiency and structural support problems occur nearly in all cases when end-to-end anastomosis of trachea is not feasible. Hyperbaric oxygen (HBO) treatment is a well-known method for the management of grafts and flaps that have vascularization problems. In this study, the effect of hyperbaric oxygen treatment on wound healing after tracheal reconstruction with auricular cartilage graft (ACG) has been evaluated.

METHODS: Thirty-two rabbits were divided into 2 groups: study group (n = 16) and control group (n = 16). The anterior halves of the six tracheal rings were resected, and the defects were repaired with autogenic auricular grafts. Hyperbaric 100% pure oxygen was administered to the study group at 2.4 atmospheres of absolute pressure 2 times a day for 1 week. The control group did not receive any therapy except proper control of the wound.

RESULTS: It was observed that in the study group, inflammation, fibrosis, and necrosis were less, whereas epithelialization and maturation were early and neovascularization and neochondrification were more than the control group only at specific weeks. But all tracheas in both groups showed excellent healing without graft rejection and excessive granulation tissue formation. Furthermore, there was no statistically difference between the 2 groups.

CONCLUSIONS: Auricular cartilage grafts is a valuable management method of tracheal defects, and hyperbaric oxygen treatment is a good supplementary method in healing period of cartilage autografts.

PMID: 14608571 [PubMed - indexed for MEDLINE]

## 10.2.7. Hyperbare Sauerstofftherapie

Welchen Effekt hat die hyperbare Sauerstofftherapie auf die Wundheilung im Vergleich zu keiner hyperbaren Sauerstofftherapie? Welchen Effekt hat die hyperbare Sauerstofftherapie im Vergleich mit anderen relevanten Verfahren? Mit welchen Effekten ist in den verschiedenen Stadien (Granulation, Exsudation) zu rechnen?

**Freier J., Welslau W.**

**Evidenz**
3 systematische Übersichtsarbeiten:
Hailey et al. 2007 (360) daraus 3 RCTs und 3 Non-RCTs (Controlled Trials) (361-366)
Hinchliffe et al. 2008 (300) daraus 1 RCT (363)
Kranke et al. 2004 (367) daraus 4 RCTs (362, 363, 366, 368)

2 RCTs:
Kessler et al. 2003 (369)
Löndahl et al. 2010 (106)

**Wirksamkeits prinzip**
Bei der hyperbaren Sauerstofftherapie (hyperbare Oxygenierung, HBO) handelt es sich um eine ergänzende therapeutische Option (adjuvante Behandlung) z einer multimodalen Therapie. HBO wird definiert als Atmung von 100 % Sauerstoff bei erhöhtem Umgebungsdruck zwischen 2,0 und 2,5 bar Gesamtdruck. Hierdurch erhöht sich die Menge des im Plasma physikalisch gelösten Sauerstoffs. Durch Sauerstoffatmung bei 2,0 bis 2,5 bar Umgebungsdruck kann eine Erhöhung des arteriellen pO auf > 1500 mmHg erreicht werden. Der pO im Gewebe und die O -Diffusion im Gewebe steigen proportional zum Anstieg des arteriellen pO. Die Hyperoxygenierung im Rahmen der HBO-Therapie soll ischämiebedingte oder aufgrund anderer Faktoren entstandene Gewebshypoxien revidieren und so pathophysiologische Regelkreise durchbrechen. Tierexperimentelle Untersuchungen zeigen einen Effekt erhöhter Sauerstoff-Partialdrücke auf die Wundheilung über die reine Hypoxiebeseitigung hinaus, wodurch es zu einer signifikant verbesserten Heilung kommt. Es wird vermutet, dass hyperbarer Sauerstoff dabei als spezifischer Signaltransducer wirkt. Im Experiment führt HBO zur Sekretion des Wachstumsfaktors TNF-a, zur Sekretion des für die Angioneogenese wichtigen Makrophagen-VEGF (Vascular endothelial growth factor) und zur Hochregulation von wachstumsfaktor-spezifischen Rezeptoren in Fibroblasten. Weiter bewirkt HBO eine dosisabhängige Stimulierung der Fibroblasten-Proliferation und deren Syntheseleistung an extrazellulärer Matrix, wie Hyaluronsäure und Proteoglykane. Daneben wurde eine Induktion von PDGF (platelet derived growth factor) -Rezeptoren nachgewiesen, eine Verringerung der systemischen inflammatorischen Reaktion sowie die Unterdrückung der bakteriellen Toxinsynthese bei Anaerobierinfektion (370-372).
Die HBO wird in spezialisierten Zentren zur Behandlung von Patienten mit diabetischem Fußsyndrom angewandt, wenn diese auf konventionelle Maßnahmen therapierefraktär sind oder durch die Schwere der Erkrankung (ab Wagner-Grad III) die Gefahr einer Amputation der Extremität besteht. Ziel der HBO ist, bei auf sonstige Maßnahmen therapierefraktären Wunden, eine Besserung bis Abheilung, ggf. die Verhinderung einer Amputation oder zumindest Verschiebung der Amputationsebene nach distal.

**Anwendungshinweise**
Das European Committee for Hyperbaric Medicine (ECHM) empfiehlt die HBO nur dann einzusetzen, wenn mittels transkutanem „Sauerstoff-Mapping“ eine pO -Erhöhung unter hyperbaren Bedingungen nachweisbar ist (373).

**Nebenwirkungen:**

Selten können durch die Therapie hyperoxiebedingte zerebrale Krampfanfälle ausgelöst werden. Die Inzidenz wird in Abhängigkeit vom Allgemeinzustand des Patienten und verschiedenen Risikofaktoren in der Literatur mit ca. 0,7 / 10.000 angegeben (374). Bei den darüber hinaus berichteten Nebenwirkungen handelt es sich in der Regel um druckbedingte Affektionen an Mittelohr und Trommelfell (Baro-trauma). Diese bedingen oft nur ein Aussetzen der HBO-Therapie für wenige Tage. Die Inzidenz wird in der Literatur mit ca. 1:100 angegeben.

**Hintergrundtext:**
Für diese Fragestellung konnten drei systematische Übersichtsarbeiten identifiziert werden, die insgesamt acht RCTs einschlossen. Zudem wurden noch zwei weitere RCTs eingeschlossen, die für die Fragestellung relevant waren. Die Arbeiten und ihre Ergebnisse werden nachfolgend dargestellt.

**Kranke et al. 2004 (367)**
Dieses Cochrane Review bewertete Nutzen und Schaden einer adjuvanten HBO-Therapie bei chronischen Ulzera der unteren Extremität. Hierzu wurden nur randomisierte, kontrollierte Studien mit Patienten mit Druckulzera, venösen, arteriellen und diabetischen Ulzera bewertet. Für die Indikation diabetisches Fußsyndrom wurden insgesamt vier Studien identifiziert (362, 363, 366, 375). Zudem wurde eine Arbeit zu venösen Ulzera (368) bewertet. Die Daten von drei Studien (362, 363, 366) mit insgesamt 118 Patienten konnten zu einer Meta-Analyse zusammengefasst werden. Sie zeigten eine Verminderung des Risikos für Major-Amputationen bei zusätzlicher Therapie mit HBO im Vergleich zu einer Standardtherapie (RR 0,31; 95%-KI 0,13 bis 0,71). Sensitivitätsanalysen hatten keinen signifikanten Einfluss auf dieses Ergebnis. Die Autoren kommen zu dem Fazit, dass die HBO-Therapie bei Patienten mit diabetischen Fußulzera das Risiko einer Major-Amputation signifikant vermindert und die Chancen auf vollständige Wundheilung nach einem Jahr möglicherweise verbessern kann. Es konnte kein statistisch signifikanter Unterschied hinsichtlich des Risikos für Minor-Amputationen gezeigt werden (RR 2,20; 95%-KI 0,65 bis 8,72). In einer Studie (366) werden Ergebnisse zu unter Behandlung abgeheilten Wunden zu verschiedenen Zeitpunkten berichtet. In der Studie zu venösen Ulcera (368) zeigte sich nach 18 Wochen Nachbeobachtungszeit im Vergleich zur Kontrollgruppe eine höhere Anzahl von abgeheilten Ulcera in der Gruppe, die mit HBO behandelt wurde. Das Ergebnis ist jedoch statistisch nicht signifikant (RR 1,31; 95%-KI 0,85 bis 2,02).

**Hailey et al. 2007 (360)**
Diese systematische Übersichtsarbeit der kanadischen HTA-Behörde zur Bewertung gesundheitsökonomischer Aspekte schloss neben den drei bereits in Kranke et al. 2004 eingeschlossenen RCTs (362, 363, 366) noch drei weitere, nicht randomisierte, kontrollierte Arbeiten (361, 364, 365) ein, die für diese Leitlinie relevant sind. In einer Meta-Analyse der sechs Arbeiten hinsichtlich der Anzahl von Patienten mit geheilten Wunden zeigte sich ein statistisch signifikanter Vorteil der HBO-Gruppe im Vergleich zur Kontrollgruppe (RR 1,95; 95%-KI 1,55 bis 2,39). Die Nachbeobachtungszeit schwankte zwischen vier und 36 Monaten und war bei der Hälfte der Studien nicht angegeben.

**Hinchliffe et al. 2008 (300)**
Die systematische Übersichtsarbeit von Hinchliffe et al. 2008 betrachtete zahlreiche Behandlungen bei diabetischem Fußsyndrom. Bezüglich der HBO-Therapie wurden fünf Arbeiten (362-364, 366, 369) eingeschlossen. Durch den breiten Fokus der Arbeit ließen sich nur Angaben für einen relevanten Endpunkt, Amputation, entnehmen. Diese basieren auf einer einzigen Studie mit 68 Patienten (363). Die Evidenz ist gering (Randomisierung unklar, keine Verblindung, chirurgische Behandlung nach Randomisierung, ungleiche Gruppen zu Studienbeginn). Es zeigte sich ein statistisch signifikanter Vorteil hinsichtlich der Anzahl der Patienten mit Amputationen (keine weiteren Angaben) nach Behandlung mit HBO im Vergleich zur Kontrollgruppe (RR 0,26; 95%-KI 0,08 bis 0,84).

**Kessler et al. 2003 (369)**
Diese randomisierte, kontrollierte Studie wurde mit 28 Menschen mit Diabetes (Typ 1 und 2) mit Ulzerationen nach Wagner-Klassifikation Grad I bis III, Abwesenheit klinischer Zeichen einer Arteriopathie und fehlender Heilungstendenz über mindestens drei Monate durchgeführt. Die Patienten der Kontrollgruppe erhielten eine konservative Therapie, die Patienten der Studiengruppe zusätzlich eine Behandlung mit hyperbarem Sauerstoff von 90 Minuten unter 2,5 bar zweimal täglich über zwei Wochen. Ein Patient wurde aufgrund eines Barotraumas aus der Studie genommen. Die Beobachtungsdauer betrug vier Wochen. In der Studiengruppe konnte eine Reduktion der Ulkusfläche um 42 % (41,8 ± 25,5) innerhalb der ersten 15 Tage beobachtet werden, in der Kontrollgruppe im Durchschnitt nur um 22 % (21,7 ± 16,9) ($p = 0,037$). Allerdings glich sich dieser Unterschied in den folgenden 14 Beobachtungstagen unter weiterer konservativer Therapie an. Die Autoren kommen daher zum Schluss, dass die hyperbare Sauerstofftherapie in der Beschleunigung der Heilung chronischer diabetischer Fußulzera wirksam ist. Aufgrund der beobachteten Angleichung der Ergebnisse in der längeren Betrachtung werden weitere, zeitabhängige Studien empfohlen. Studiendesign und Studiendurchführung wurden in der

GRADE-Systematik mit „moderat“ bewertet. Allerdings ist die Fallzahl klein und hinsichtlich der Vergleichbarkeit der Gruppen fehlt eine Gegenüberstellung der Studiengruppen nach Wagner-Graden. Aussagen über die Rate vollständiger Heilungen und über den langfristigen Therapieerfolg können nicht getroffen werden.

**Löndahl et al. 2010 (106)**
Bei der HODFU-Studie (Hyperbaric Oxygen Therapy in Diabetics with Chronic Foot Ulcers) handelt es sich um eine randomisierte, monozentrische, doppelt verblindete, Placebo-kontrollierte klinische Studie. In dieser Studie wurde die Wundheilung beim DFS unter HBO untersucht. Es fanden über einen Zeitraum von acht Wochen 40 Druckkammerbehandlungen mit 100 % Sauerstoff bzw. Raumluft (Schein-HBO) in Kombination mit einer Standardtherapie ambulant statt. In diese Studie wurden nur Patienten eingeschlossen, die Wunden aufwiesen, welche in einem Zeitraum von > 3 Monaten nicht verheilt waren. Außerdem wurden nur Patienten eingeschlossen, die eine adäquate periphere Perfusion aufwiesen oder nach Ausschöpfung der Revaskularisationsmöglichkeiten. Die Einteilung der Wunde erfolgte nach der Wagner-Klassifikation (Wagner II bis IV). Als Ausschlusskriterium galten gefäßchirurgische Eingriffe in den letzten zwei Monaten, chronische Lungenerkrankungen (COPD) und Alkohol- bzw. Drogenkonsum. Während der ganzen Untersuchung wurden die Patienten nach internationalem Standard in einer diabetologischen Schwerpunkteinrichtung behandelt. Die Nachuntersuchungen erfolgten jeweils wöchentlich bis zur zehnten Woche und dann in einem Intervall von drei Monaten bis zu dem Endpunkt nach einem Jahr. Als primärer Endpunkt galt die abgeheilte Wunde. Als sekundärer Endpunkt mit Studienende galt eine Major-Amputation oder der Tod des Patienten. Anhand der GRADE-Methodik wird die Qualität der Evidenz als „hoch“ bewertet. In der Intention-to-treat (ITT)-Analyse wurde eine komplette Heilung de Ulcus für mindestens ein Jahr Nachbeobachtungszeit bei 37 Patienten erreicht: in der HBO-Gruppe bei 25/48 (52 %) und in der Kontrollgruppe bei 12/42 (29 %) (RR 2,14; 95%-KI 1,18 bis 3,88). Auch nach einem Jahr Nachbeobachtung war die Heilungsrate der lange vorbestehenden chronischen Ulcera in der HBO-Gruppe doppelt so hoch wie in der Kontrollgruppe (RR 2,19; 95%-KI 1,19 bis 4,01).

**Fazit**
Zusammenfassend ist festzustellen, dass alle Studienergebnisse gleichgerichtet sind und positive Effekte der HBO darstellen. Der aussagekräftigste patientenrelevante Endpunkt ist in der Reduktion der Major-Amputationsrate durch die HBO-Therapie zu sehen. Für diesen Endpunkt liegt die höchste Ergebnissicherheit aus der Meta-Analyse zugunsten der HBO-Therapie vor. Eine beschleunigte Wundheilung ist unter Berücksichtigung der oben angeführten erheblichen Beeinträchtigung der Lebensqualität von Patienten mit diabetischem Fußsyndrom ebenfalls als patientenrelevanter Endpunkt zu werten. Auch diesbezüglich sind die Ergebnisse der HBO positiv, jedoch von geringerer Validität, da in den Studien nicht immer die vollständige Wundheilung als Endpunkt gewählt wurde. Dabei ist zu berücksichtigen, dass die Mehrzahl der in den Studien behandelten Patienten entweder höhere Wundschweregrade (Wagner Grad > I) oder komplizierte Heilungsverläufe (Infektionszeichen, fehlende Heilungstendenz innerhalb von 30 Tagen) aufwiesen. Die Behandlung in der als aussagekräftigste identifizierten Studie von Löndahl et al. 2010 (106) erfolgte zudem nach einem interdisziplinären Behandlungskonzept unter Einschluss konservativer und invasiver Diagnose- und Therapieverfahren. Nach GRADE werden die meisten berücksichtigten Studien hinsichtlich der Studienqualität (quality) als „moderate“ bewertet, eine Studie mit „high“ (106).

Insgesamt führt die vorliegende Datenlage zur Leitlinien-Empfehlung, die Hyperbare Sauerstofftherapie **sollte** bei Patienten mit diabetischem Fußsyndrom nach Ausschöpfen von Revaskularisationsmaßnahmen bei amputationsbedrohter Extremität als zusätzliche Therapieoption verwendet werden. Die Stärke dieser einstimmig konsentierten Empfehlung entspricht der Qualität der vorliegenden Daten.

2001 • 3 [Supp12]: S267—S271 © Springer-Verlag
2001

Wolf Mutschler' Claus-Martin Muth[2] • Frank Rösken[1]
'Chirurgische Klinik und Poliklinik, Klinikum Innenstadt, Universität München
[2]Universitätsklinik für Anästhesiologie, Ulm

# Stellenwert der hyperbaren Sauerstofftherapie bei chronischen Wunden

## Zusammenfassung

Chronische Wunden sind Defektwunden, die sich nicht oder nur mangelhaft verschließen, weil sie die Trias Nekrose, Hypoxie und Azidose nicht überwinden können und in einer sich perpetuierenden Entzündungsreaktion verharren. Im Rahmen eines 8-stufigen Therapiealgorithmus aus konservativen und operativen Maßnahmen kann die HBO dann sinnvoll eingesetzt werden, wenn ein messbares Hypoxieproblem vorliegt. Indikationen für chronische Ulzera,Voraussetzungen der Patienten,technische Durchführung und Kosten werden dargestellt. Zellbiologische und tierexperimentelle Untersuchungen sowie klinische Studien der Evidenzklasse I und II belegen, dass mit der HBO als additiver Therapie beim diabetischen Fußsyndrom eine eindrückliche Senkung der Makroamputationsrate erreicht werden kann, dass die Wundheilungsrate bei chronisch-venösen Ulzera zu steigern ist und die Erhaltung nekrosegefährdeter Haut-Muskel-Knochen-Transplantate in bestrahlten Gebieten deutlich häufiger möglich ist. Die HBO kann nicht mehr länger als „eine Therapie auf der Suche nach ihren Indikationen" bezeichnet werden.

## Schlüsselwörter

Chronische Wunden • Hyperbare Oxygenierung • Additive Therapie . Ergebnisse

Chronische Wunden sind Defektwunden, die sich nicht, mangelhaft oder nicht dauerhaft verschließen und somit den physiologischen Ablauf der Wundheilung mit den 4 Phasen:

1. Entzündung,
2. Proliferation,
3. epithelialisiertes Narbengewebe und
4. Remodelling,

nicht nachvollziehen können. Klassische Vertreter chronischer Wunden sind die (infizierte) große traumatische Defektwunde, das Dekubitalulkus, das chronisch-venöse Ulkus, die Wunde bei PAVK, das diabetische Fußsyndrom und die Wunde im bestrahlten Gebiet. All diesen chronischen Wundformen ist gemeinsam, dass letztlich die Trias Nekrose, Hypoxie und Azidose zur Überforderung der zellulären Abwehrleistung führt, das Bakterienwachstum in der Wunde fördert und die Ausbildung eines geordneten Granulationsgewebes und Epithels verhindert. Stattdessen resultiert eine sich perpetuierende Entzündungsreaktion mit einer Überrepräsentation und Überaktivierung von Makrophagen, der permanenten Freisetzung proinflammatorischer Zytokine und der Blockierung von Entzündungsinhibitoren, der Degradation der extrazellulären Matrix und der Störung der Zell-Zell-Interaktionen [io, 15, 22].

Ziel der Behandlung von chronischen Wunden muss es folglich sein, diesen sich selbst unterhaltenden Entzündungsprozess zu durchbrechen und die geordnete Proliferation in der Defektwunde zu ermöglichen. Eine hierauf aufgebaute, topische und systemische, phasen- und zeitadaptierte Wundtherapie besteht aus 8 Bausteinen [15]:

1. der Identifizierung und Behandlung intrinsischer und extrinsischer Ursachen,
2. der Beseitigung von Nekrosen durch chirurgische, enzymatische oder *Biological-surgery-Ma* ßnahmen,
3. der Verbesserung der Gewebeperfusion und dem Anheben des Sauerstoffpartialdrucks in der Wunde,
4. der Schaffung eines physiologischen Wundmilieus ohne Infektion zur Induktion eines gut vaskularisierten Granulationsgewebes (z. B.feuchte Wundbehandlung),
5. der Unterstützung des Aufbaus von Granulationsgewebe und des Epithels (z. B. durch Wachstumsfaktoren,Applikation von Matrixbausteinen,Inhibierung und Reaktivierung der Signaltransmission),
6. dem definitiven Defektverschluss durch Spalthauttransplantation,artifizielle Gewebeersatzmaterialien, Keratinozyten oder Haut-Muskel-Transfer,
7. der Hilfsmittelversorgung, Patientenanleitung, außerklinischen Kooperation und

Prof. Dr.Wolf Mutschler
Chirurgische Klinik und Poliklinik,
Klinikum Innenstadt, Universität München,
Nussbaumstraße 20,80336 München
(E-Mail:Wolf Mutschler@ch-i.med, uni-muenchen.de,
Te1.:089-51602501,Fax:089-51604437)

Trauma Berufskrankh
2001 • 3 [Suppl 2]: S267—S271 © Springer-Verlag 2001

**W. Mutschler • C.-M. Muth • F. Rösken**

# Value of hyperbaric oxygen relative to other therapies for chronic wounds

**Abstract**

Chronic wounds are defined as long-lasting defects in which necrosis, hypoxia,and acidosis cannot be overcome,so that continuous inflammation is present.This in turn means that insufficient granulation tissue develops, or even none at all,and re-epithelialization is delayed or impossible. I n such problem wounds as diabetic foot syndrome, infected traumatic soft tissue defects or decubital ulcers hyperbaric oxygen therapy (HBO) can be useful when there is a quantifyable problem with hypoxia, providing it is viewed as one option in an 8-step-algorithm including conservative and operative procedures. Indications, patient suitability criteria, transcutaneous 02 measurement technique, technical standards and costs are presented. Studies in cell cultures and experimental animals in addition to clinical studies (evidente dass I and II) clearly demonstrate that HBO given as an adjunctive therapy reduces the rate of major am putations in diabetic foot syndrome and improves the wound healing rate in chronic varicose ulcers. In addition, after HBO graft or flap failure is less frequent in tissue that is poorly vascularized as a result of irradiation. HBO can no longer be described, as it was in the past, as "a therapy in search of diseases".

**Keywords**

Chronic wounds • Hyperbaric oxygen • Additive therapy • Restifts

## Therapeutische Alternativen

8. der Langzeitbeobachtung und Qualitätskontrolle.

Im Rahmen dieses Therapiealgorithmus hat die hyperbare Sauerstofftherapie (HBO) ihren Platz als adjuvante Therapie (Baustein 3). Sie ist dort effektiv, wo ein chronischer Sauerstoffmangel herrscht und der lokale Sauerstoffpartialdruck im kompromittierten Gewebe zu niedrig ist.

## Wirkung der Therapie

Nach den Untersuchungen von Hunt [to] ist das Zentrum der Wunde hypoxisch, azidotisch, hypoglykämisch, hyperkapnisch, hyperkaliämisch und laktatbeladen. Dieser gravierende Milieuunterschied zum hyperämischen Wundrand ist physiologisch und löst die gerichtete Zellmigration und Gefäßaussprossung aus, aber nur, wenn der Wundrand gut oxigeniert ist. Dies gewährleistet die HBO. Sie hat durch ihr Wirkprinzip - Erhöhung des Anteils physikalisch gelösten Sauerstoffs und Vergrößerung der Sauerstoffdiffusionsstrecke im Gewebe - vielfältige, in der Zellkultur und im Tierversuch eindeutig nachgewiesene Effekte: Sie verbessert die Oxygenierung des Wundrands und reduziert die Hypoxie im Wundgrund sowie das Wundödem. Sie erhöht die Kollagensynthese und Angioneogenese-rate und induziert die Zellproliferation. Sie steigert die Phagozytosefähigkeit von Makrophagen, ist bakteriostatisch bei aeroben Keimen und bakterizid bei Anaerobiern und inaktiviert bakterielle Toxine. Damit trägt sie dazu bei, den perpetuierten Entzündungsprozess Richtung Proliferation und damit Richtung Ausbildung eines gut vaskularisierten Granulationsgewebes zu verschieben [14, 20, 22] .

Der Erfolg einer HBO-Therapie als additive Therapie ist an 2 Bedingungen geknüpft:

1. Ausgedehnte Nekrosen und Infektionen sind durch ein chirurgisches Debridement vorher makroskopisch beseitigt.
2. Eine Hypoxie allein oder (wie meist) in Kombination mit anderen Faktoren ist mit Ursache für die Wundheilungsstörung bzw. chronische Wunde und lässt sich durch eine Erhöhung des P02 beseitigen.

Ein guter Messparameter hierfür ist der transkutan gemessene P0,-Wert im Wundgebiet („Sauerstoff-Mapping" der Wunde).

Liegt der transkutane Sauerstoffwert unter Normoxie und normobaren Bedingungen < 3o-4o mm Hg, gilt die hypoxische Wundheilungsstörung als gesichert. Wenn unter normobarer Sauerstoffatmung ein Anstieg des $tP0_2$ erfolgt, ist die Indikation zum Therapieversuch gegeben. Es werden dann die Werte in Wundnähe und in einem nicht kompromittierten Referenzbereich unter hyperbaren Bedingungen gemessen. Werte < ioo mm Hg zeigen an, dass die HBO-Therapie nutzlos ist. Bei Werten zwischen ioo und 300 mm Hg ist mit einem Ansprechen auf die Therapie zu rechnen, bei Werten > 700 mm Hg ist die Prognose als gut zu betrachten [22].

Für Patienten mit chronischen Wunden hat sich die 1-mal am Tag durchgeführte Behandlung mit Sauerstoffatmung bei 2,4 x $io^5$ Pa (2,4 bar) und einer Gesamtexpositionszeit von 135 min international durchgesetzt. 20-40 Behandlungstage sind die Regel, > 6o Behandlungen sollten nicht durchgeführt werden. An Kosten sind derzeit DM 8000,00-24.000,00 anzusetzen. Diese Summe errechnet sich aus dem Preis pro Behandlung (etwa DM 400,00) und der Anzahl der Behandlungen (20- bis 6o-mal). Die ambulante Durchführung der Maßnahme ist die Regel [22].

## Fallbeispiel

Der männliche Patient (R. E.), geboren 1923, erlitt 1943 eine Schussfraktur am rechten distalen Unterschenkel mit einer chronisch rezidivierenden, jetzt ruhenden Osteomyelitis und einer 8 x 3 $cm^2$ großen, am Knochen adhärenten Narbenplatte medial-ventral am Übergang vom mittleren zum distalen Unterschenkeldrittel. Im Februar z000 brach diese instabile Narbe auf, das Narbengewebe ging zugrunde. Es entwickelte sich eine Defektwunde von 9 cm Längsdurchmesser und 6,5 cm Querdurchmesser, die sich mit *E. coli,* hämolysierenden Streptokokken und einer anaeroben Mischflora besiedelte und unter konservativen Maßnahmen nicht zur Ausheilung kam (Abb. 1 a, b). Es bestanden eine periphere AVK, Stadium V (Großzehenkuppennekrose), eine ausgeprägte Arteriosklerose der Becken-

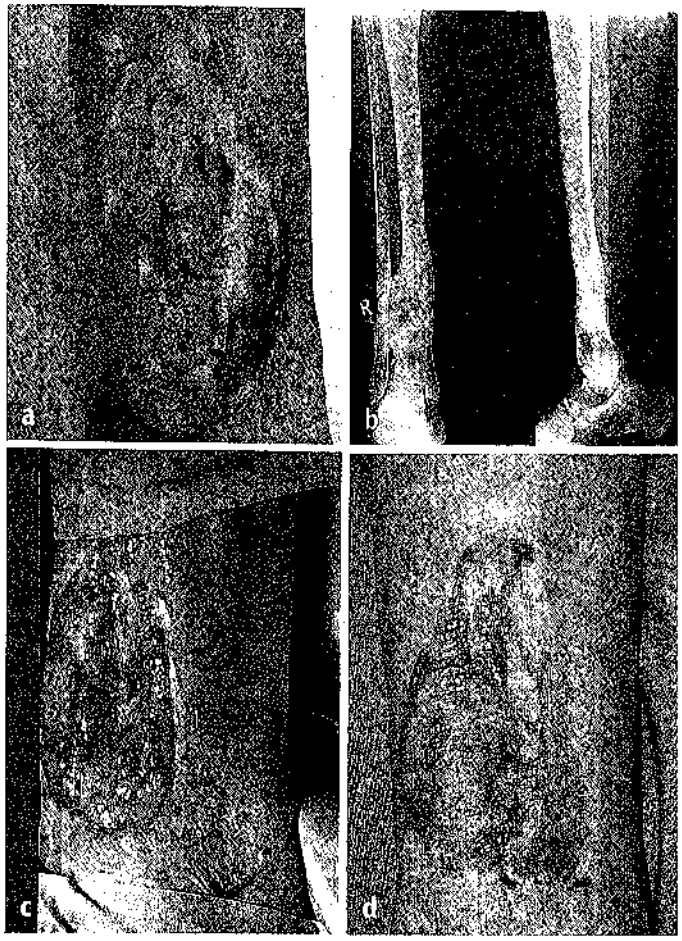

Abb. 1 a-d ◆ **Fallbeispiel R. E.,** a **Ausgangssituation distaler Unterschenkel, Weichteile,** b **Ausgangssituation distaler Unterschenkel, Röntgenaufnahme,** c **Granulationsgewebe nach HBO,** d **Spalthautdeckung**

strombahn beidseits mit einer 80%igen Stenose der A. iliaca externa, einer mittelgradigen Stenose der A. femoris communis rechts, einem Verschluss der A. femoralis superficialis rechts, einem Verschluss der A. tibialis posterior rechts und 2 verbleibenden, arteriosklerotisch veränderten Gefäßen am distalen Unterschenkel.

Sonstige Risikofaktoren waren; Status nach Herzinfarkt und Bypassoperationen, kompensierte Niereninsuffizienz sowie Parkinson-Symptomatik.

4 Monate nach Aufbrechen der Narbe und nach erfolgter konservativer Therapie anderenorts wurde erstmals ein Wunddbridement, gefolgt von einer lokalen fibrinolytischen Therapie, durchgeführt. 4 Tage später folgten die Anlage eines venösen femoro-popliteal-en Bypass, verbunden mit der Aufdehnung der proximal davon liegenden Gefäßstenosen und ein erneutes Wunddébridement. Der Knochen lag jetzt über 6 cm avaskulär frei. 6 Tage später wurde der Knochen angemeißelt und bei beginnenden Granulationen v. a. über der Sehne des M. tibialis anterior ein Okklusivverband (feuchte Wundbehandlung) angelegt. Am Tag danach wurde mit der HBO nach dem Problemwundenschema begonnen. Nach 12 Sitzungen war die gesamte Wunde so von gutem Granulationsgewebe überzogen, dass die Spalthautdeckung vorgenommen werden konnte (Abb. 1 c), welche 5 Tage später eine sichtbare Einheilung zeigte (Abb. id). Während der gesamten Behandlungszeit erfolgte eine systemische, spezifische, antibiotische Therapie. Ein plastischer Eingriff zur Deckung der Defektwunde war aufgrund der Gefäßsituation nicht möglich.

Dieses Beispiel soll verdeutlichen, dass es notwendig ist, den oben angeführten Therapiealgorithmus jeweils individuell anzuwenden und die HB 0 dabei als eine additive Maßnahme zu versehen.

## Mit der HBO erzielbare Ergebnisse

Welche Ergebnisse sind gesamt gesehen mit der HBO als adjuvanter Therapie bei chronischen Wunden zu erzielen? Ausgewählte klinische Studien hierzu sind in Tabelle 1 enthalten. Aufgeführt sind Studien der Evidenzklasse I (randomisierte, prospektive Studien analog GCP-Standard) oder Evidenzklasse II. Während die Wirkung der HBO auf chronische Wunden in der Zellkultur und im Tierexperiment eindeutig nachgewiesen wurde, sind viele klinische Studien zu dieser Thematik insofern angreifbar, als dass es sich in der Mehrzahl nicht um prospektive, randomisierte, verblindete Studien handelt. Dies haben diese Studien allerdings mit fast allen anderen klinischen Studien bei chronischen Wunden, z. B. zur Anwendung von Wachstumsfaktoren oder Ähnlichem, gemeinsam, da grundsätzliche methodische Probleme bestehen, bei chronischen Wunden Studien der Evidenzklasse durchzuführen. Mit dieser Einschränkung zeigen die zitierten Studien einen Therapieeffekt der HBO, der in der Bewertung nicht zu unterschätzen ist, weil es sich jeweils um chronische Wunden handelte, die für längere Zeit therapierefraktär blieben und bei denen die HBO oft als Ultima Ratio eingesetzt wurde.

Die meisten Erfahrungen mit HBO liegen bei chronischen Wunden im Rahmen des diabetischen Fußsyndroms vor. Behandlungsziele sind

- die Verhinderung einer Amputation *(major amputation)* oder
- die Verminderung des Amputationsausmaßes *(minor amputation)* oder
- die Vorbereitung der Wunde zum plastischen Verschluss.

Wird die HBO in Kombination mit gefäßchirurgischen oder interventionellen Gefäßeingriffen, mit einer rationalen lokalen Wundkonditionierung und unter der Kontrolle durch Sauerstoff-Mapping durchgeführt, sind die Raten an vermeidbaren Amputationen eindrücklich [1, 7, 17].

Für das Ulkus auf dem Boden einer peripheren arteriellen Verschlusskrank-

Tabelle 1
**Ausgewählte klinische Literatur zur HBO bei chronischen Wunden**

| Autor | Zeitschrift | Wunde | Studie | n | Zielkriterien | Ergebnis |
|---|---|---|---|---|---|---|
| Faglia et al. [7] | Diabetes Care 1996 | DFS[a] | Prospektiv-randomisiert | 68 | Amputationsrate | 33,3% / 8,6% |
| Baroni et al. [1] | Diabetes Care 1987 | DFS | Prospektiv-kontrolliert | 28 | Wundheilung | 10% / 89% |
| Oriani u. Faglia [17] | Undersea Hyperb Med 1995 | DFS IV | Kontrolle | 115 | Amputationsrate | 47% / 13,9% |
| Hammerlund u. Sundberg [9] | Plast Reconstr Surg 1994 | Venöses Ulcus cruris | Prospektiv-randomisiert, doppelblind | 16 | Wundverkleinerung nach 6 Wochen | 2,7% / 35,7% |
| Bass [2] | Postgrad Med J 1970 | Venöses Ulcus cruris | Anwendungsbeobachtung | 19 | Wundheilung | 89% |
| Bouachour et al. [3] | J Trauma 1996 | Crush-Verletzung | Prospektiv-randomisiert, doppelblind | 36 | Heilung und Reeingriffe | 10/10 Patienten / 17/1 Patienten |
| Neovius et al. [16] | Head Neck 1997 | Radiatio | Historische Kontrolle | 30 | Wundheilung nach plastischer Deckung | 7/15 Patienten / 12/15 Patienten |
| Perrins [18] | Lancet 1967 | Spalthautdeckung | Kontrollgruppe | 48 | Einheilung | 17% / 64% |
| Bowersox et al. [4] | J Hyperbar Med 1986 | Ischämischer Hautlappen | Historische Kontrolle | 105 | Verlustrate | 67% / 10% |

[a] *DFS diabetisches Fußsyndrom*

heit ohne sonstige Risikofaktoren liegen nach unserem Wissen keine Studien, sondern nur Einzelbeobachtungen zur HBO vor.

Für das venöse Ulcus cruris wurden gegenüb er einer herkömmlichen konservativen Therapie eindrückliche Wundverkleinerungen beschrieben [2,19].

Bewährt hat sich die HBO auch als additive Maßnahme für plastische Eingriffe in vorbestrahlten Gebieten sowie zur Unterstützung der Einheilung von Spalthauttransplantaten und zur Rettung von nekrosegefährdeten Haut-Muskel-Lappen bei Patienten mit systemischen und lokalen Risikofaktoren [4, 11,16,18].

Mit Einfügung der HB 0 in den Therapieplan wurde die Anwendung osteointegrierter Implantate auch für Patienten erschlossen, die wegen Kopf-Hals-Tumoren mit 65-7o Gy bestrahlt wurden. Die HBO beeinflusst hier die Wundheilung gesichert positiv, reduziert das Risiko einer Osteoradionekrose und erlaubt die osteointegrative Verankerung von Gebissen, Alloplastiken und Epithesen mit einer Erfolgsrate von > 95% gegenüber etwa 55-86% ohne HBO [12,13].

Zum Einsatz der HBO bei chronischen Dekubitalulzera liegen nur Einzelbeobachtungen vor.

Auch zur Therapie der chronisch refraktären Osteitis mit chronisch fistelnden Wunden liegen noch keine eindeutigen Erkenntnisse vor [6].

Bei Crush-Verletzungen mit und ohne Frakturen zeichnet sich ab, dass ein Übergang in eine chronische Defektwunde verhindert oder vermindert werden kann und die Zahl der notwendigen Reeingriffe durch die HBO sinkt [3].

## Resümee

Die hyperbare Sauerstofftherapie hat bei chronischen Wunden einen gesicherten therapeutischen Effekt. Zahlreiche experimentelle Ergebnisse belegen vielfältige Effekte auf den Ablauf der normalen und gestörten Wundheilung. Die Durchführung der Therapie bei Problemwunden ist mittlerweile international standardisiert. Die Einschluss- und Ausschlusskriterien sind gut definiert. Die Kosten sind angesichts des chronischen Verlaufs und der sich damit anhäufenden Kosten allein für die gängige

konservative Therapie vertretbar und überschaubar.

Eine Rationale für die Anwendung der HBO bei den lebensbedrohlichen Erkrankungen arterielle Gasembolie, Dekompressionsunfall, CO-Vergiftung, Gasbrand und nekrotisierende Weichteilinfektionen ist inzwischen weltweit gegeben [5, 20]. Für die therapierefraktäre Wunde mit Gewebehypoxie, die nekrosegefährdeten Haut-Muskel-Knochen-Transplantate, für den ausgedehnten Weichteilschaden mit drohendem Gewebeuntergang, für die ausgedehnte Verbrennung und für die Prävention und Therapie einer Osteo- oder Weichteilradionekrose ist die HBO als adjuvante Maßnahme inzwischen gut abgesichert einzusetzen, auch wenn noch wenig aussagekräftige klinische Studien der Evidenzldasse I vorliegen. Es ist jedenfalls nicht mehr gerechtfertigt, die HBO als *„eine Therapie auf der Suche nach Krankheiten"* zu beschreiben [8].

## Literatur


1, Baron) G, PorroT, Faglia E, Pizzi G,Mastropasqua A, Oriani G, Pedesini G, Favales F (1987) Hyperbaric oxygen in diabetic gangrene treatment.Diabetes Care 10:81-86

2. Bass BH (1970) The treatment of varicose leg ukers by hyperbaric oxygen. Postgrad Med J 46:407

3. Bouachour G, Cronier P,GouelloJP,Toulemonde 1L,Talha A,Alquier P (1996) Hyperbaric oxygen therapy in the management of crush injuries:a randomized double-blind placebo-controlled clinical tria1,1 Trauma 41:333-339

4. Bowersox JC,Strauss MB, Hart GB (1986) Clinical experience with hyperbaric oxygen therapy in the salvage of ischemic skin Raps and grafts. 1 Hyperbar Med 1:141

5. Clark LA, Moon RE (1999) Hyperbaric oxygen in the treatment of life-threatening soft-tissue infections.Respir Care Cl in N Am 5:208-219

6. Esterhai Pisarello1, Brighton CT,Heppenstahl RB,Gellman H,Goldstein G (1987) Adjunctive hyperbaric oxygen therapy in the treatment of chronic refractory osteomyelitis. 1Trauma 27:763-768

7. Faglia E, Favales F,Aldeghi A, Calia P,Quarantiello A, Oriani G, Michael M, Campagnoli P, Mora bito A (1966) Adjunctive systemic hyperbaric oxygen therapy in treatment of severe prevalently ischemk diabetic foot ulcer - a randomized study. Diabetes Care 19:1338-1343

8. Gabb G, Robin ED (1987) Hyperbaric oxygen:a therapy in search of diseases.Chest 92: 1074 - 1082

9. Hammerlund C, Sundberg T (1994) Hyperbaric oxygen reduced size of chronic leg ulcus:a randomized double-blind study. Plast Reconstr Surg 93:829-833

10. HuntTK (1988) The physiology of wound healing.Ann Emerg Med 17:1265-1273

11. Kindwall EP, Gottlieb U, Larson DL (1991) Hyperbaric oxygen therapy in plastic surgery: a review article. Plast Reconstr Surg 88:898-908

12. Larsen PE (1997) Placement of dental implants in the irradiated mandible:a protocol involving adjunctive hyperbaric oxygen.1 Oral Maxillofac Surg 55:967-971

13. Marx RE, Ehler WJ,Tayapongsak P, Pierce LW (1990) Relationship of oxygen dose to angiogenesis induction in irradiated tissue.Am 1 Surg 160:519-524

14. ;Nutschier W, Muth CM (2001) Hyperbare Sauerstofftherapie in der Unfallchirurgie. Unfallchirurg 104:102-114

15. MutschlerW,Rösken F (1999) Problematik der chronischen Wunde. In: Steckmeier B, MutschlerW (Hrsg) Münchner Gefäßtage 9.-10.7,1999, Diagnostik und Therapie der fortgeschrittenen peripheren arteriellen Verschlusserkrankung, München, S 43-48

16. Neovius EB, Lind MG, Lind FG (1997) Hyperbaric oxygen therapy for wound complications after surgery in the irradiated head and neck: a review of the I iterature and a report of 15 consecutive patients, Head Neck 19:315-322

17. Oriani E, Faglia E (1995) Hyperbaric oxygen treatment in the diabetic gangrene. Undersea Hyperb Med [Suppl] 22:11

18. Perrins DJD (1967) Infiuence of hyperbaric oxygen an the survival of split skin grafts. Lancet 1:868

19. Rabkin JM,HuntTK (1988) Infection and oxygen.In:Davis JC,HuntTK (eds) Problem wounds. Elsevier, New York, pp 1-16

20. Tibbles PM, Edelsberg JS (1996) Hyperbaric oxygen therapy. N Engl J Med 334:1642-1648

21. Wattel F, Mathieu D, Coget 1M, Billard V (1990) Hyperbaric oxygen therapy in chronic vascular wound management. Angiology 41:59-65

22. Welslau W, Rinneberg G, Almeding M,Tirpitz D (1998) Hyperbare Sauerstofftherapie. Archlmedes, Göttingen

Grundmann T.; M Jaehne; G Fritze: Der Stellenwert der hyperbaren Sauerstofftherapie in der Behandlung von Problemwunden im Bereich der plastisch-rekonstruktiven Kopf-Hals-Chirurgie . Laryngorhinootologie. 2000 May; 79(5):304-10

Univ. HNO-Klinik, UKE, Hamburg

BACKGROUND: Hyperbaric oxygenation therapy is presently predominantly discussed in connection with sudden deafness and tinnitus. Amongst this ongoing controversy, the primary indications of this in the middle of the 20th century established therapy, especially in regard to problem wounds in the plastic-reconstructive surgery go mainly underrated. The present paper reviews the attention towards this area in plastic surgery.

PATIENTS AND METHODS: Three typical cases (traumatic nasal tip reconstruction, wound ulceration after radiotherapy and lobe necrosis together with fistula following laryngopharyngectomy) are presented.

RESULTS: Because of protracted and complicated wound healing HBO was applied in all three cases, eventually leading to very satisfying subconsequent wound-healing. In connection with these cases, the underlying problems and the effects of HBO are discussed.

SUMMARIZING: The authors conclude, that HBO primary clinical application in treatment of problematic wound healing in head and neck appears to be very effective and helpful and should not be underrated whilst discussing this therapy in different contexts.

Hammarlund C, T Sundberg: Hyperbaric oxygen reduced size of chronic leg ulcers: a randomized double-blind study. Plast Reconstr Surg. 1994 Apr ;93 (4):829-33; discussion 834 8134442 (P,S,E,B)

Department of Anaesthesia, Helsingborg Hospital, Sweden.

To evaluate the effect of hyperbaric oxygen therapy on chronic wound healing, 16 otherwise healthy patients who had nondiabetic, chronic leg ulcers with no large vessel disease were included in a **double-blind study**.

Patients were grouped according to age and then randomly assigned to two groups breathing either air or oxygen at 2.5 atmospheres of absolute pressure for 90 minutes 5 days per week for a total of 30 treatments. The wound area was copied onto transparent film covering the wound and then measured using only one matching wound from each patient.

The mean decrease of the wound areas at weeks 2, 4, and 6 in the oxygen group were 6 percent (SD +/- 14), 22 percent (SD +/- 13), and 35.7 percent (SD +/- 17), respectively, and in the air group, 2.8 percent (SD +/- 11), 3.7 percent (SD +/- 11), and 2.7 percent (SD +/- 11), respectively, giving a p value less than 0.05 at week 4, and a p value less than 0.001 at week 6 between the groups using the Mann-Whitney U test.

These data indicate that hyperbaric oxygen therapy may be used as a valuable adjunct to conventional therapies when nondiabetic wounds do not heal.

# Literaturstellenübersicht

## ( Chirurgie Plastische + HBO - alphabetisch sortiert )


Al-Waili NS, Butler GJ, Petrillo RL, Carrey Z, Hamilton RW.: Hyperbaric oxygen and lymphoid system function: a review supporting possible intervention in tissue transplantation. Technol Health Care. 2006;14(6):489-98.

Angel MF, Im MJ, Chung H-K, et al': Effects of combined cold and hyperbaric oxygen storage on free flap survival. Microsurgery 15:648-651, 1994.

Arnold PG, Lovich AF, Pairolero PC: Muscle flaps in irradiated wounds: An account of 100 consecutive cases. Plast Reconstr Surg 93:324-327, 1994.

Ashauer et al. 1980 Transcutaneous p02 in flaps: a new method of survival prediction Plast. Reconstr. Surg. 65 738-45

Basset BE, Bennett PB. Introduction to the physical and physiological basis of hyperbaric therapy. In: Davis JC, Hunt TK, eds. Hyperbaric oxygen therapy. Bethesda, MD: Undersea Medical Society, 1977:11–24.

Bill, T. J., Hoard, M. A., and Gampper, T. J. Applications of hyperbaric oxygen in otolaryngology head and neck surgery: facial cutaneous flaps. Otolaryngologic Clinics of North America 2001; 34 (4): 753-66

Bowersox et al.:1987 Hyperbaric oxygen treatment in the management of threatened skin flaps and grafts in : Proc 8th Int Congr Hyperb Med Best Publishing Comp , 149-152 +

Bowersox JC, Strauss MD, Hart GB. Clinical experience with hyperbaric oxygen therapy in the salvage of ischemic skin flaps and grafts. J Hyperbaric Med 1986;1:141–9.

Boykin JV, Eriksson E, Pittman RN: In vivo microcirculation of a scald burn and the progression of postburn dermal ischemia. Plast Reconstr Surg 66:191, 1980.

Buslau et al.: 1993 Die hyperbare Oxygenation (HBO) - eine adjuvante Therapie akuter und chronischer Wundheilungsstörungen Dermatologische Monatsschrift 179, 39-54 +

Buslau et al.: 1992 Hyperbaric oxygen therapy in the treatment of skin deseases in : Fuchs et al (Hrsg): Oxidative Stress in Dermatology NY 1994 +

Byrne JB, Egnaczak S, Pons P, McCaffrey J : HYPERBARIC OXYGEN FOR SALVAGE OF BELOW-KNEE AND TRANS-METATARSAL AMPUTATION FLAPS UHM 2008, Vol. 35, No. 4 — Abstracts from UHMS ASU 2008.

Champion WM, McSherry CK, Goulian D: Effect of hyperbaric oxygen on the survival of pedicled skin flaps. J Surg Res 7:583-586, 1967.

Cianci P, Lenders HW, Lee H, et al: Hyperbaric oxygen and burn fluid requirements: Observations in 16 patients with 40% to 80% TBSA burns (abstract). Undersea Biomed Res 15:14S, 1988.

Cianci P, Lueders HW, Lee H, et al: Hyperbaric oxygen therapy reduces length of hospitalization in thermal burns. J Burn Care Rehabil 10:432-435, 1989.

Cianci P, Sato R: Adjunctive hyperbaric oxygen therapy in the treatment of thermal burns; a review. Burns 20:5-14, 1994.

Cianci P, Williams C, Lueders H, et al: Adjunctive hyperbaric oxygen in the treatment of thermal burns: An economic analysis. J Burn Care Rehabil 11:140-143, 1990

Collins et al. : 1991 The effect of nicotinamide and hyperbaric oxygen on skin flap survival scand J Plast reconstr surg hand surg 25,5-7

Dellinger 1981 Severe necrotizing soft tissue infections JAMA 246, 15

Doctor N, Pandya S, Supe A: Hyperbaric oxygen therapy in diabetic foot. J Postgrad Med 38:112-114,1992.

Dorod et al. 1983 Measurement of transcutaneous oxygen pressure in ormal and ishemic skin J. Bone Joint Surg. 65, 79-83

Eltorai I: Hyperbaric oxygen in the management of pressure sores in patients with injuries to the spinal cord. J Dermatol Surg Oncol 7:737-740, 1981.

FINDERLE Z, CANKAR K, STRUEL M.: The effect of HBO therapy on skin microcirculation in a frostbite injury victim: Case report. P. 174 In: Collection of manuscripts for the XXIV Annual Scientific Meeting of the European Underwater and Baromedical Society, Gennser, M, ed. Stockholm, Sweden.1998. 234 pp. Undersea and Hyperbaric Med. 14 (1999) +

Friedman HI, Fitzmaurice M, Lefaivre JF, Vecchiolla T, Clarke D. An evidence-based appraisal of the use of hyperbaric oxygen on flaps and grafts. Plast Reconstr Surg. 2006;117: 175S-190S. Eskes AM, Ubbink DT, Lubbers MJ, Lucas C,

Frigerio et al.: 1992 Effect of hyperbaric oxygenation on the survival of experimental skin flaps in rats in : Proc 10th Int Cong. Hyperb. Med. Best Publishing Comp. 1992, 199-201 +

Gozal et al 1986 Necrotizing fasciitis Arch. Surg. 121, 233-5

Greenwood TW, Gilchrist AG: Hyperbaric oxygen and wound healing in postirradiation head and neck surgery. Br J Surg 60:394-399, 1973.

Grundmann T.; M Jaehne; G Fritze: Der Stellenwert der hyperbaren Sauerstoffthera-pie in der Behandlung von Problemwunden im Bereich der plastisch-rekonstruktiven Kopf-Hals-Chirurgie . Laryngorhinootologie. 2000 May; 79(5):304-**10**

Hart GB, O'Reilly RR, Broussard ND, et al: Treatment of burns with hyperbaric oxygen. Surg Gynecol Obstet 139:693, 1974.

Harward 1985 Oxygen inhalation - induced transcutaneous p02 changes as an predictor of Amputation level J. vasc. Surg. 2, 220-7

Hauser 1987 Tissue salvage by mapping of skin surface transcutaneous oxygen tension index Arch. Surg. 122, 1128-30

Hirn et al 1990 Necoritizing fasciitis treated with surgery, antibiotics and hyperbaric oxygen in EUBS 1990 proc Amsterdam Foundation Hyperb Med 219-25

HOLLABAUGH RS JR, DMOCHOWSKI RR, HICKERSON WL, COX CE.:

Fournier's gangrene: therapeutic impact of hyperbaric oxygen. Plast Reconstr Surg 101 (1998) 94 - 100.

Hunt TK, Nunikoski J, Zederfeldt BH, et al. Oxygen wound healing enhancement: cellular effects of oxygen. In: Davis JC, Hunt TK, eds. Hyperbaric oxygen therapy. Bethesda, MD: Undersea Medical Society, 1977:111–13.

Im MJ, Shen WH, Pak CJ, et al: Effect of allopurinol on the survival of hyperemic island skin flaps. Plast Reconstr Surg 73:276-278, 1994.

Kaelin CM, Im MJ, Myers RAM, et al: The effects of hyperbaric oxygen on free flaps in rats. Arch Surg 125:607-609, 1990.

Kernahan DA, Zingg W, Kay CW: The effect of hyperbaric oxygen on experimental skin flaps. Plast Reconstr Surg 36:19-25, 1965.

Ketchum SA, Thomas AN, Hall AD: Angiographic studies of the effect of hyperbaric oxygen on burn wound revascularization. in Wada J, Iwa T (eds): Hyperbaric Medicine. Williams & Wilkins. Baltimore, 1969, pp 388-394.

Ketchum SA, Zubrin JR, Thomas AN, et al: Effect of hyperbaric oxygen an small first, second, and third degree burns. Surg Forum 18:65-67, 1967.

Kindwall et al. : 1991 Hyperbaric oxygen therapy in plastic surgery - A review article Plast reconstr. Surg 88, 898-908

KORHONEN K, KLOSSNER J, HIRN M, NIINIKOSKI J.: Management of clostridial gas gangrene and the role of hyperbaric oxygen. Ann Chir Gynaecol 1999;88(2):139-42. Undersea and Hyperbaric Med. 14 (1999) +

Laman et al. 1992 Hyperbaric oxygen and Mohs micrographic surgery in the treatment of osteoradionecrosis and recurrent cutaneous carcinoma J Dermatol Surg Oncol (USA) 18, 579-83

Lipski + 1994 Chirurgische Erstbehandlung des schweren offenen und geschlossenen Weichteiltraumas in Tirpiz (Hrsg):Therapie mit hyperbarem Sauerstoff (HBO) in Traumatologie und Notfallmedizin Symposium Duisburg 1993Springer 33 - 36

LOZANO DD, STEPHENSON LL, ZAMBONI WA.: Effect of hyperbaric oxygen and medicinal leeching on survival of axial skin flaps subjected to total venous occlusion. Plast Reconstr Surg 1999 Sep;104(4):1029-32. Underwater and Hyperbaric Med. 15 (2000) 228 +

Lucca et al. 1990 Treatment of fourniers gangrene with adjunctive hyperbaric oxygen therapy Am J emerg med 8, 385-7

Manson et.al.: 1980 Improved capillaries by hyperbaric oxygen in skin flaps Surg. Forum 31, 564-6

Manson PN, Anthenelli RM, Im MJ, et al: The role of oxygen-free radicals in ischemic tissue injury in island skin flaps. Ann Surg 198:87-90, 1983.

Manson PN, Narayan KK, Im MJ, et al: Improved survival in free skin flap transfers in rats. Surgery 99:211-214, 1986.

Mathieu et al.: Pedicle musculocutaneuous flap transplantation: Prediction of final outcome by transcutaneous oxygen measurements in hyperbaric oxygen in : Proc 10th Int Cong. Hyperb. Med. Best Publishing Comp. 1992, 149-155 +

May JW. Chait LA, O'Brien BM, et al: The no-reflow phenomenon in

experimental free flaps. Plast Reconstr Surg 61:256, 1978.

McFariane RM, Wermuth RE: The use of hyperbaric oxygen to prevent necrosis in experimental pedicle flaps and composite skin grafts. Plast Reconstr Surg 37:422-430, 1966.

Nemiroff et al.: Effects of hyperbaric oxygen and irradiation on experimental skin flaps in rats Otolaryngol Head Neck Surg, 1985; 93: 485-91 +

Nemiroff PM: Hyperbaric oxygen in skin grafts and flaps. Hyperb Med Pract 28:566-579, 1994.

Nemiroff: Hyperbaric oxygen in skin grafts and flaps. in Kindwall ( Hrsg). Hyperbaric Medicine Practice Best Publishing Comp. 1994, 565-80 +

Nemiroff: Synergistic effects of pentoxyfylline and HBO on skin flaps Otolaryngol Head Neck Surg, 1988; 114: 977-81 +

Nichter LS, Morwood DT, Williams GS, et al: Expanding the limits of composite grafting: A case report of successful nose replantation assisted by hyperbaric oxygen therapy. Plast Reconstr Surg 87:337-40, 1991.

Nui AKC, Yang C, Lee HC, et al: Burns treated with adjunctive hyperbaric oxygen therapy: A comparative study in humans. Presented at 9th International Symposium an Underwater and Hyperbaric Physiology, Undersea and Hyperbaric Medical Society, 967-976, 1987.

Nylander et al.:1985 Reduction of postischemic edema with hyperbaric oxygen plast. Reconstr. Surg. 76, 596-601

Nylander G, Lewis D, Nordstrom H, et al. Reduction of postischemic edema with hyperbaric oxygen. Plast Reconstr Surg 1985;76:595–603.

Nylander G, Nordstrom H, Eriksson E: Effects of hyperbaric oxygen on oedema formation after a scald burn. Burns 10:193, 1984.

Nylander G, Nordstrom H, Franzen L, et al: Effects of hyperbaric oxygen treatment in post-ischemic muscle (A quantitive morphological study). Scand J Plast Reconstr Surg 22:31-39, 1988.

Pang CY; Ischemia-induced reperfusion injury in muscle flaps: Pathogenesis and major source of free radicals. J Reconstr Microsurg 6:77-83, 1990.

Perrins: Influence of hyperbaric oxygen on the survival of split skin grafts. Lancet I, 1967; 868-871

Reinisch JF. Pathophysiology of skin flap circulation. The delay phenomenon. Plast Reconstr Surg 1974;54:585–98.

Reinisch JF. The role of arteriovenous anastomoses in skin flaps. In: Grabb WC, Myers MBG, eds. Skin flaps. Boston: Little, Brown, 1975:81–92.

Roberts GP, Harding KG: Stimulation of glycosaminoglycan synthesis in cultured fibroblasts by hyperbaric oxygen. Br J of Dermatol 131:630-633, 1994.

Sawin et al.+ 1994 Early recognition of neonatal abdominal wall necrotizing fasciitis am. J. Surg. 167, 481-484

Shoshani 0; Shupak A; Ullmann Y; Ramon Y; Gilhar A; Kehat I; Peled IJ.: The effect of hyperbaric oxygenation on the viability of human fat injected into nude mice. Plastic and reconstructive surgery 2000 Nov; 106 (6), pp. 139066; discussion 1397-8.

SHOSHANI O, ULLMANN Y, SHUPAK A, RAMON Y, GILHAR A, LAVON H, PELED IJ.: The effect of hyperbaric oxygenation on the viability of injected adipose tissue - an experimental study in nude mice. P. 12 In: Proceedings of the 25th Annual Meeting of the EUBS on Diving, Hyperbaric Medicine and High Pressure Biology, jointly with the 2nd Annual Meeting of the Israel Society for Hyperbaric and Diving Medicine and Physiology, eds. Shupak A, Lincoln, R, Grossman Y. 1999 Aug 28-Sept 2, Haifa and Eilat, Israel. 279 Pp. Undersea and Hyperbaric Med. 14 (1999) +

Shulman et al.: The influence of hyperbaric oxygen in multiple skin grafts on the healing of skin wounds. Surgery 1967; 62: 1051

Skyhar MJ, Hargens AR, Strauss MB, et al: Hyperbaric oxygen reduces edema and necrosis of skeletal muscle in compartment syndromes associated with hemorrhagic hypotension. J Bone Joint Surg Am 68-A:1218-1224, 1986.

Tai YJ, Birely BC, Im MJ, et al: The use of hyperbaric oxygen for preservation of free flaps. Arm Plast Surg 28:284-287, 1992.

Tompach PC, Lew D, Stoll JL. Cell response to hyperbaric oxygen treatment. Int J Oral Maxillofac Surg 1997; 26:82-86.

Ueda M, Kaneda T, Takahashi H, et al: Hyperbaric oxygen therapy of ischemic skin flaps: Clinical and experimental study. Presented at the 9th International Symposium on Underwater and Hyperbaric Physiology, Undersea and Hyperbaric Medical Society, 1987.

Vedder N: Improved random flap survival with monoclonal leukocyte antibodv. Plast Reconstr Surg 93:1035-1040, 1994.

Wang C, Schwaitzberg S, Berliner E, Zarin DA, Lau J. Hyperbaric oxygen for treating wounds. A systematic review of the literature. Arch Surg. 2003;138:272-279.

Wattel F, Pellerin P, Mathieu D, Patenotre P, Coget JM, Schoofs M, Leps P.: [Hyperbaric oxygen therapy in the treatment of wounds, in plastic and Ann Chir Plast Esthet. 1990;35(2):141-6.

Welslau + 1991 Nekrotisierende Weichteilinfektionen und HBO-Therapie Caisson 7, 169

Yamada T, Taguchi T, Hirata Y: The effect of hyperbaric oxygenation on ischemia-reperfusion injury of the small intestine. Transplantation Proc 26:1506-1507, 1994.

YUCEL A, BAYRAMICLI M. :Effects of hyperbaric oxygen treatment and heparin on the survival of unipedicled venous flaps: an experimental study in rats. Ann Plast Surg 2000 Mar;44(3):295-303.

Zamboni WA, Roth AC, Russell RC, et al: The effect of acute hyperbaric oxygen therapy on axial pattern skin flap survival when administered during and after total ischemia. 1 Reconstr Microsurg 5:343-347, 1989.

Zamboni WA, Roth AC, Russell RC: Morphologic analysis of the microcirculation during reperfusion of ischemic skeletal muscle and the effect of hyperbaric oxygen. Plast Reconstr Surg 91:1110-1123, 1993.

Zamboni WA, Shah HR. Skin grafts and flaps (compromised). In: Feldmeier JJ, ed, Hyperbaric Oxygen 2003: Committee Report. Kensington, MD: Undersea and Hyperbaric Medical Society, 2003:101–7.

# Weitere Anwendungsgebiete für die Hyperbare Medizin

**Indikationsliste entsprechend der**
**Undersea and Hyperbaric Medical Society UHMS, USA; Club Francais de Medicine Hyperbare; European Undersea Biomedical Society EUBS Europäischen Committees für Hyperbare Medizin ( ECHM ), der Deutschen Gesellschaft für Tauch- und Überdruckmedizin ( GTÜM )**

## 1. Hyperbare Sauerstofftherapie nachdrücklich empfohlen ( strongly recommended )

Dekompressionskrankheit ( Caisson )
Arterielle Gasembolie
CO-Vergiftung ( neurol., psychiatr., psycholog. Auffälligkeiten, Schwangerschaft )
Verbrennungskrankheit und CO-Vergiftung
Nekrotisierende Weichteilinfektion - Gasbrand
Zahnextraktion in bestrahltem Gebiet

## 2. Hyperbare Sauerstofftherapie empfohlen ( recommended )

akuter Hörsturz

| | |
|---|---|
| diabetische Wunde wenn | $tcpO_2$ bei 2,5bar wundnah > 200 mmHg oder RR im Zehenbereich > 40 mmHg |
| AVK bedingte Wunde wenn | $tcpO_2$ bei 2,5bar wundnah > 100 mmHg oder RR Fesselbereich > 75 mmHg |

Osteoradionekreose
Weichteilnekrose (nicht Enteritis, Myelitis)
chronisch refraktäre Osteomyelitis
Osteomyelitis Schädel, Sternum
Crush-Verletzung ( secundär )
Hirnabszeß

## 3. Hyperbare Sauerstofftherapie sinnvoll ( optional )

Weichteilnekrose ( Enteritis, Myelitis )
Crush-Verletzung ( akut )
Kompartmentsyndrom ( akut )
postanoxischer ZNS-Schaden ( akut )
Verbrennungskrankheit ( > 20% KOF 2°, akut)
Migräne - Kopfschmerz + Cluster
Schlaganfall
Hirnoedem - Schädel-Hirn-Traumen
retinale Zentralarterieninsuffiziens
therapieresistente Pilzinfektionen